

Trigeminal Branch Stimulation for Intractable Neuropathic Pain: Technical Note

Konstantin V. Slavin, MD ■ Christian Wess, MD

Department of Neurosurgery, University of Illinois at Chicago, Chicago, Illinois

■ ABSTRACT

Intractable neuropathic facial pain resulting from injury to the peripheral branches of the trigeminal nerve presents a significant challenge for neurologists, pain specialists, and neurosurgeons. In this paper, we describe our technique of peripheral nerve stimulation of the infraorbital and supraorbital nerves to treat patients with medically intractable facial pain. Stimulation of the infraorbital and supraorbital nerves is performed using percutaneously inserted electrodes that are positioned in the epifascial plane, traversing the course of the infraorbital or supraorbital nerves. The temporary electrodes are inserted under fluoroscopic guidance and are anchored to the skin. A trial lasting a few days is followed, if successful, by insertion of a permanent electrode that is tunneled under the skin behind the ear toward the infraclavicular pocket, which houses the implantable pulse generator. Our technique of electrode insertion to stimulate the infra-

orbital or supraorbital nerves has been successfully used in several patients with neuropathic trigeminal pain of various etiologies. In patients who underwent permanent electrode implantation, stimulation resulted in long lasting pain relief; complications were rare and minor. We conclude that trigeminal branch stimulation is a simple technique that can be used in selected patients with neuropathic pain in the distribution of the infraorbital or supraorbital nerves. This procedure may provide relief of medically intractable pain, without the need for destructive procedures or more central modulation approaches. ■

KEY WORDS: infraorbital, nerve stimulation, neuromodulation, neuropathy, supraorbital, trigeminal neuropathic pain

INTRODUCTION

The treatment of medically intractable facial pain is a challenging issue. Although treatments for certain types of pain, such as trigeminal neuralgia, are well established, trigeminal neuropathic pain that results from an injury involving one or several

peripheral branches of the trigeminal nerve is often difficult to control with current medical and surgical approaches (1). When the standard combination of anti-inflammatory, anticonvulsant, and antidepressant medications fails, patients are frequently offered local medication injections, percutaneous or open destructive procedures, and, in rare cases, neuromodulation using either deep brain or motor cortex stimulation. Direct stimulation of the trigeminal system has also been tried by placing electrodes next to the Gasserian ganglion, but this approach was reported not to be reliable.

Address correspondence and reprint requests to: K. V. Slavin, MD, Department of Neurosurgery (M/C 799), 912 South Wood Street, Chicago, IL 60612. Email: kslavin@uic.edu.

The peripheral nerve stimulation approach based on the gate-control theory of pain has been successfully used for more than 30 years in the treatment of neuropathic pain syndromes resulting from peripheral nerve damage (2,3). Recently, percutaneous insertion of peripheral nerve stimulation electrodes has been proposed for the treatment of neuropathic pain in the occipital area (4). Burchiel began using a similar approach to treat neuropathic facial pain in 1997 (5,6), but the technical details of this procedure have not been published so far.

We have been using peripheral trigeminal stimulation at the University of Illinois at Chicago since 1999. In this paper, we present a step-by-step description of the technique based on our experience. A summary of clinical information from the first eight patients for whom this approach was tried is also presented.

METHODS AND MATERIALS

Patient Selection

In our opinion, patients are candidates for chronic stimulation of the trigeminal nerve branches if the following criteria are met:

- 1 The pain is chronic (lasting longer than three months) and either severe or moderate-to-severe in intensity (higher than 5 on a 0–10 visual analog scale (VAS) of pain intensity).
- 2 The pain follows the anatomic distribution of one or more peripheral trigeminal branches.
- 3 The onset of the pain is temporally related to a traumatic, inflammatory, or surgical event.
- 4 Standard treatment with anti-inflammatory/analgesic medications, antidepressants, and anticonvulsants was tried and failed, either because the medications were only minimally effective or because they caused intolerable side effects.
- 5 The patient maintains some sensation in the area of pain.
- 6 The patient has undergone formal neuropsychological evaluation and has been found to be an appropriate candidate for a surgical pain-relieving procedure.
- 7 The pain disappears or significantly improves after local anesthetic block of the affected branch(es) of the trigeminal nerve.

- 8 The patient has no active infection and no bleeding disorders, and is able to tolerate brief general anesthesia.

All these criteria are important, but their importance and value for each patient should be considered on a case-by-case basis.

Description of the Technique

The surgery is done in two stages and is similar to the approach used in spinal cord stimulation. During the first stage, a temporary electrode is inserted in the vicinity of the targeted nerve branch. This is followed by a trial of stimulation that lasts several days. If the trial is successful, the second stage of surgery involves insertion of a permanent electrode that is anchored and tunneled to an implantable pulse generator.

The technique described below can be used for both infraorbital and supraorbital nerve stimulation (Fig. 1). Both of these nerves are located in relatively immobile areas, so electrodes placed in their vicinity tend not to move from the initial position. We have not used this technique in the highly mobile mandibular area because of the risk of electrode displacement.

The first surgery is done under intravenous sedation or general anesthesia. It has been our experience that patients with chronic facial pain are usually unable to tolerate the insertion of a

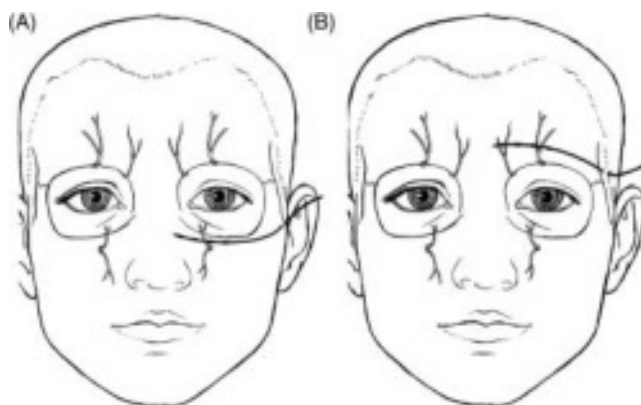


Figure 1. Schematic drawing of a supraorbital (A) and infraorbital (B) quadripolar electrodes showing the electrode location relative to the course of the infraorbital and supraorbital nerves. Note the entry point for each electrode located lateral to the orbit.

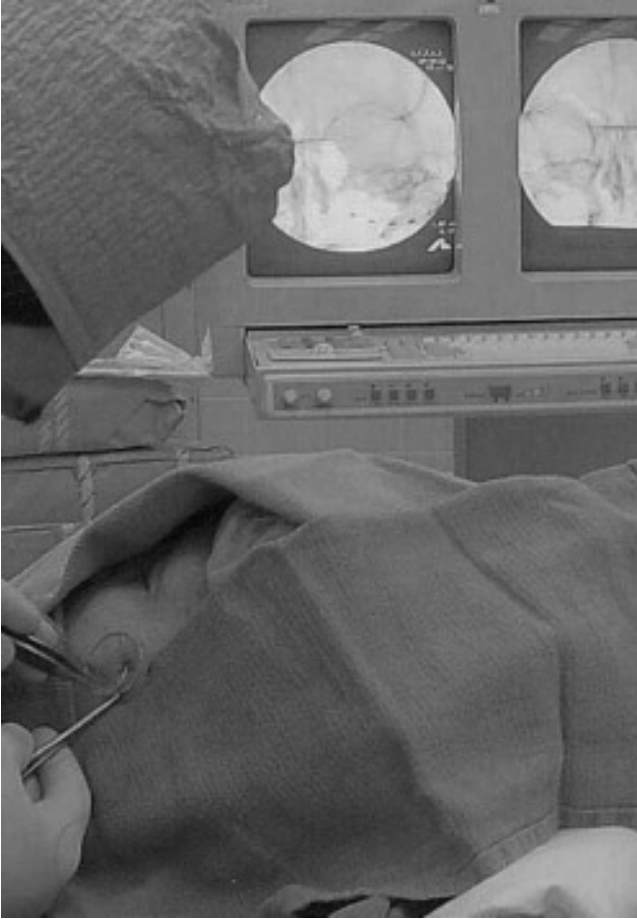

Figure 2. Intraoperative photograph of left infraorbital electrode insertion.

rather large needle into the face under local anesthesia. Preparation is done in the usual fashion and a fluoroscopy machine (C-arm) is positioned around the patient's head to allow an anteroposterior view of the head during electrode insertion (Fig. 2). Although the entire procedure can be done in an outpatient setting, we prefer to use the regular operating room because sterile conditions, a dedicated C-arm, and appropriate anesthesia support are essential to prevent procedure-related complications.

A standard quadripolar electrode designed for percutaneous approach for spinal cord stimulation (Pisces Quad, Medtronic Inc., Minneapolis, MN, or Quatrode, ANS Inc., Plano, TX) is inserted at a point three to four cm lateral to the corner of the eye through a small stab incision (Fig. 1). A standard Tuohy needle, which is provided with the electrode, is slightly bent so it can follow the

curve of the patient's skull. Before insertion, the electrode is passed through the needle to make sure it will not be trapped by the needle's curvature.

When the supraorbital nerve is the stimulation target, the needle is aimed toward the midline about one cm above the supraorbital ridge (Fig. 1A). After the needle stylet is removed, the electrode is advanced under live fluoroscopy until its tip reaches the needle opening. The first electrode contact is placed about one cm from the midline. Although the supraorbital nerve cannot be directly visualized with fluoroscopy, its position is relatively constant, and the electrode always crosses the nerve's course as it passes out of the supraorbital foramen or groove (Fig. 3).

For infraorbital nerve stimulation, the entry point is lateral and inferior to the corner of the eye, over the zygoma (Fig. 1B). The needle is also bent first, and then inserted toward the side of the nose parallel to the inferior border of the orbit and one cm inferior to it. If the infraorbital foramen is visible under fluoroscopy, the electrode is placed across it; if the foramen cannot be clearly identified, placing the first electrode contact next to the side of the nose usually results in the electrode crossing the nerve's path as it exits the foramen (Fig. 4).

After the electrode is placed in the desired location, the needle is removed and the electrode is coiled around the entry point and anchored to the skin with two 4-0 nylon sutures. This is done to provide some strain relief and prevent electrode displacement during the trial. The electrode is covered with sterile dressing and connected to the screening device cable.

Once the patient recovers from sedation or general anesthesia, he or she is instructed on the use of the screening device. Initial screening settings are chosen based on the patient's perception of paresthesias in the distribution of the supraorbital or infraorbital nerve. The goal, as with spinal cord or other peripheral nerve stimulation, is to cover the entire painful zone with painless paresthesias. The patient is instructed to continue normal activities but to avoid getting the electrode wet.

The trial usually lasts five to seven days, during which the patient records the pain intensity and the stimulation effects or side effects experienced during the trial. The patient is allowed to adjust the stimulation settings (primarily the amplitude

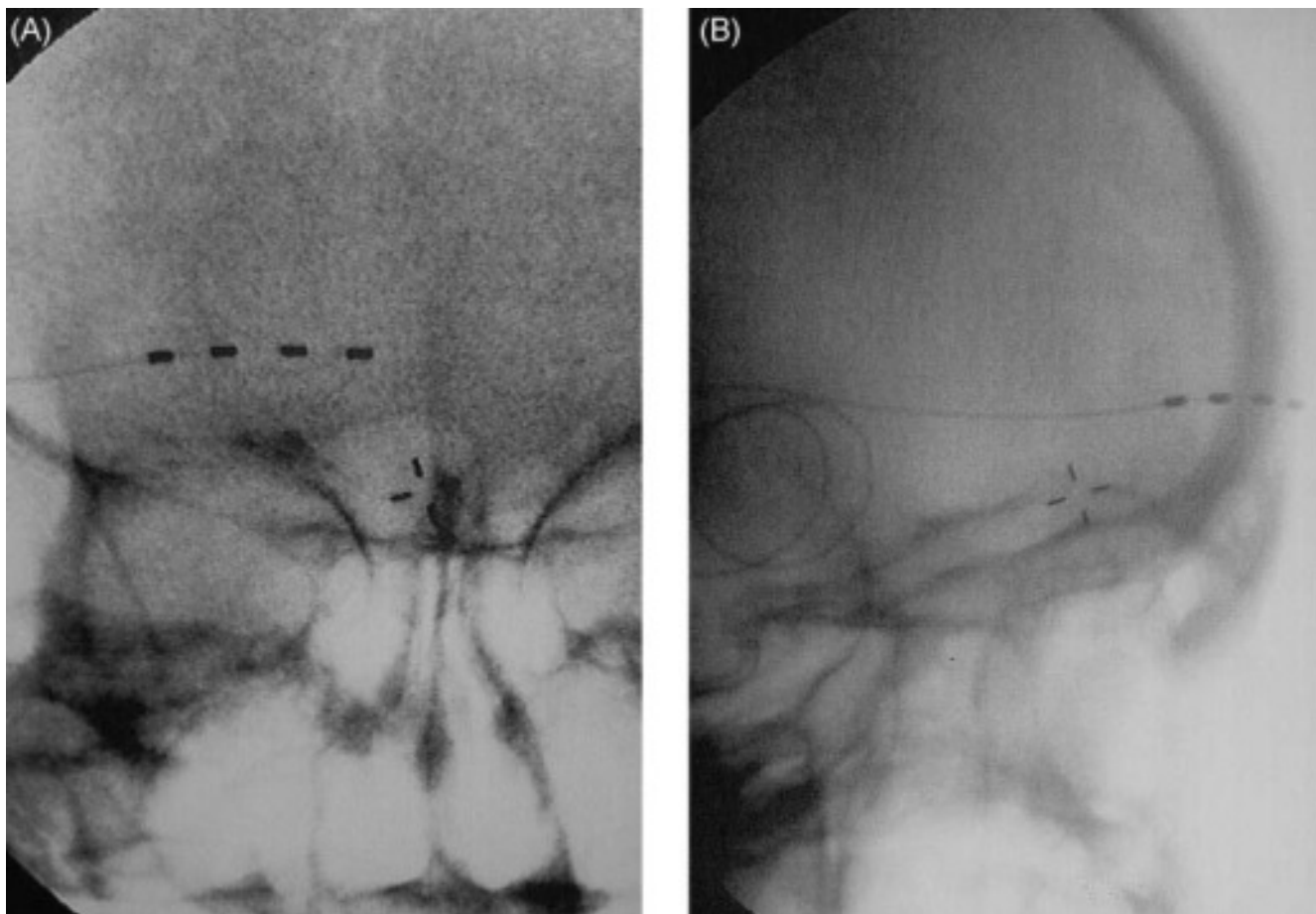


Figure 3. Radiographs of the supraorbital electrode (A, anteroposterior; B, lateral).

and frequency of stimulation) depending on activities of daily living, level of pain, and/or side effects related to the stimulation. The polarity of electrode contacts and pulse width of stimulation may be changed as well, but these adjustments are done by medical personnel only. We routinely keep the patient on oral antibiotics, although there is no evidence that this affects the infection rate.

The trial is considered successful if the patient reports more than 50% pain relief with stimulation. If the trial fails, the electrode can be removed in the office or clinic by simply removing the sutures and pulling the electrode out. No sutures are required to close the entry incision. If the trial is successful, the temporary (trial) electrode is removed before implantation of the permanent system.

The second stage of the procedure is always done under general anesthesia. The patient is positioned supine on the operating table and the head is rotated toward the side opposite the painful

area. Sterile preparation includes the painful side of the face, the area above and behind the ear for electrode anchoring and tunneling, and the ipsilateral side of the neck all the way to the infraclavicular area where the pulse generator will be implanted. The fluoroscopy machine is once again positioned around the patient's head to provide an anteroposterior view of the skull. The electrode is inserted in the same way as the temporary electrode. An incision is then made behind the ear and the electrode's back end is tunneled toward it using a "needle-over-the-styles" technique in which the stylet is passed toward the retroauricular incision, and then the needle is passed toward the electrode over the stylet. The electrode is threaded into the needle and the needle is removed, bringing the electrode toward its anchoring point behind the ear. The electrode is fixed in place with regular plastic anchors provided in the kit and nonabsorbable sutures.

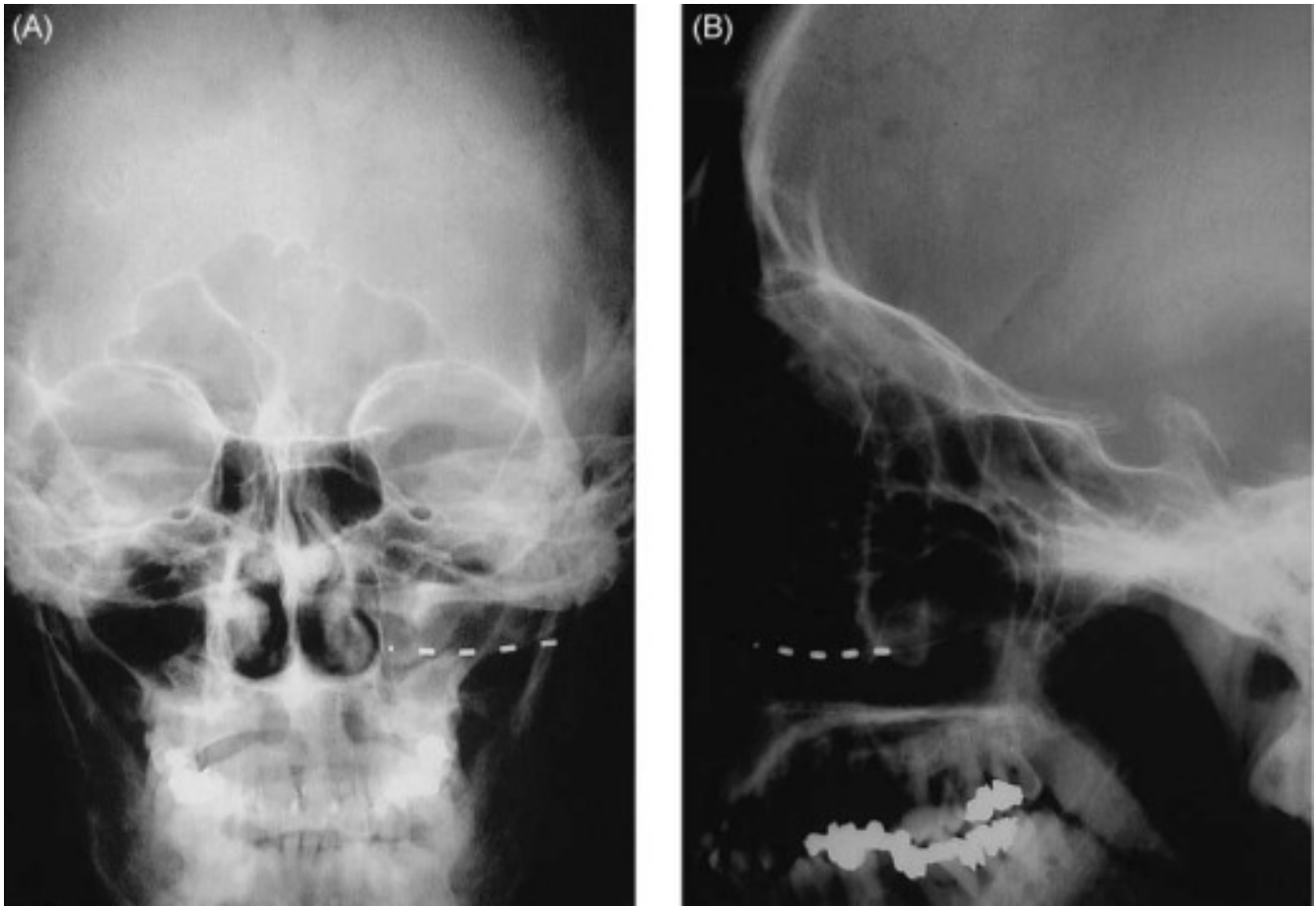


Figure 4. Radiographs of the infraorbital electrode (A, anteroposterior; B, lateral).

From the retroauricular incision, the extension cables are tunneled toward a third incision that is made below the clavicle, in a similar fashion to that used for tunneling extension cables for deep brain or motor cortex stimulators. The implantable pulse generator is placed in a subcutaneous pocket below the clavicle, where it is anchored to the thoracic fascia with nonabsorbable sutures after all connections are secured. We prefer to place the connection between the electrode and the extension cable immediately adjacent to the retroauricular incision to make any future revisions easier.

All incisions are irrigated with antibiotic solution. After thorough hemostasis, the retroauricular and infraclavicular incisions are closed in layers, and the electrode insertion site is closed with a single nylon suture. Throughout the procedure, fluoroscopy is used to confirm that the electrode crosses the path of the target nerve.

Postoperatively, the stimulator's parameters are set for optimal paresthesias/pain relief coverage. The patient is instructed on how to adjust the stimulation settings (amplitude, pulse width, and frequency of stimulation may be changed using an external controller within a preset range), since the intensity of the pain and the response to stimulation can fluctuate.

Clinical Data

We tried this technique in eight patients (Table 1) over three-year period (2000-03). Seven patients experienced more than 50% improvement in pain intensity during the stimulation trial and proceeded with implantation of permanent system. During the follow-up, two patients were re-operated. One had the system removed 26 months after implantation due to gradual loss of the beneficial effect of stimulation and overall improvement of the

Table 1. Summary of Clinical Data

Number of patients	8
Age (years)	51 (39–73)
Gender (male/female)	2/6
Location of pain	Infraorbital—4, supraorbital—5 (both areas in one patient)
Duration of pain (years)	4.4 (2–8)
Cause of pain	3—surgery, 2—trauma, 3—infection
Preoperative VAS score	8.1 (7–9)
Pain relief > 50% during trial	7/8
Length of follow up (months)	27.5 (13–50)
VAS score reduction at latest follow up (%)	74 (63–86, 6 patients)
Complications	1—electrode erosion
Notes	One patient had bilateral SON PNS, two patients had occipital PNS in addition to SON or ION electrodes, and one patient had SON and ION electrodes on same side. ^a

^aION, infraorbital nerve; PNS, peripheral nerve stimulation; SON, supraorbital nerve

pain intensity. Another patient developed skin erosion over the supraorbital electrode requiring temporary removal of the electrode followed by electrode re-insertion three months later.

DISCUSSION

Trigeminal neuropathic pain can result from different types of nerve damage. Traumatic injury of the peripheral branches of the trigeminal nerve, neuropathy due to inflammation involving the maxillary or frontal sinus, various sinus surgeries, and other pathologic processes can all cause chronic pain in the distribution of the affected nerve. Most of the time, this pain responds to standard medical treatment, which includes anti-inflammatory medications, anticonvulsants (such as gabapentin or carbamazepine), and antidepressants (such as amitriptyline or nortriptyline). Local anesthetic blocks may be used both for diagnostic confirmation of the nerve involvement and for temporary pain relief.

Medically intractable pain is usually treated with peripheral denervation procedures (7). These include open transection or avulsion of the nerve responsible for the pain, and radiofrequency or chemical destruction of the nerve using a percutaneous approach. These techniques may relieve the pain but produce permanent numbness in the nerve distribution. Two significant problems associated with destructive procedures are the possible return of pain after the nerve regenerates and the potential for the development of painful numbness (anesthesia dolorosa), which may be much more disabling than the original pain.

Incomplete or only transient pain relief may also be explained by central sensitization phenomenon that is present in these chronic pain patients.

Neuromodulation has been successfully performed for a variety of neuropathic pain syndromes, ranging from persistent radiculopathy in patients with “failed back surgery” syndrome to complex regional pain syndromes (CRPS) type 1 and 2. In more intractable cases, deep brain stimulation and motor cortex stimulation have been used to control pain in the body and in the face; both modalities have resulted in long-term pain relief. Central neuromodulation procedures, however, carry risks associated with the electrode insertion, and these risks may be unacceptable to some patients.

Peripheral nerve stimulation, on the other hand, is an established modality that has been used for several decades in the treatment of various neuropathic pain syndromes (8,9). It is based on the gate-control theory of pain (10), which postulates that impulse transmission in the nociceptive afferent pathway is modulated by activity in large-caliber myelinated non-nociceptive A-fiber afferents. According to this theory, “flooding” the hypothetical gate with non-nociceptive information may temporarily suppress the pain. Peripheral nerve stimulation is an example of a so-called paresthesia-inducing pain-relieving modality, and provides evidence supporting the gate theory (2,3).

Pain in the face area is a very complicated phenomenon. Some of the wide variety of pain syndromes may be interrelated (11). Certain facial pain syndromes, such as typical trigeminal neuralgia, have a relatively straightforward treatment algorithm, whereas others are harder to manage.

A group of procedures that involve stimulation of the Gasserian ganglion using either percutaneous (12) or open (13) approaches has been suggested for neuropathic facial pain. These techniques, however, are much more invasive and have not gained much popularity in the 20 years since they were first described (14). One of the reasons the Gasserian stimulation was less effective was high rate of electrode migration; this particular problem is less likely to happen with our technique since the electrode is positioned in a relatively immobile area and the anchoring is done close to the electrode contacts.

Our technique for treating trigeminal neuropathic pain is not a panacea, and is not intended for the treatment of migraines, headaches, or trigeminal neuralgia. It is also unlikely to help patients with anesthesia dolorosa, as this modality requires at least some preservation of sensation that can generate and transmit non-nociceptive information toward the “gate” of the pain system.

Our preliminary experience with eight patients is insufficient for us to make firm recommendations in regard to this procedure; however, we believe the technique may become part of the neurosurgical armamentarium. In the future, as experience with the treatment of the trigeminal neuropathic pain using peripheral nerve stimulation grows, we will be able to compare various treatment modalities for both efficacy and safety, perhaps allowing us to determine a first-line treatment for medically intractable facial pain.

REFERENCES

1. Slavin KV, Burchiel KJ. Surgical options for facial pain. In: Burchiel, KJ, ed. *Surgery for Pain*. New York: Thieme Medical Publishers, 2002:850-864.
2. Sweet WH, Wepsic JG. Treatment of chronic pain by stimulation of fibers of primary afferent neuron. *Trans Am Neurol Assn* 1968;93:103-107.
3. Wall PD, Sweet WH. Temporary abolition of pain in man. *Science* 1967;155:108-109.
4. Weiner RI, Reed KL. Peripheral neurostimulation for control of intractable occipital neuralgia. *Neuro-modulation* 1999;2:217-231.
5. Slavin KV, Burchiel KJ. Peripheral nerve stimulation for painful nerve injuries. *Contemp Neurosurg* 1999;21:1-6.
6. Slavin KV, Burchiel KJ. Use of long-term nerve stimulation with implanted electrodes in the treatment of intractable craniofacial pain. *J Neurosurg* 2000;92:576 (abstr.).
7. Burchiel KJ, Slavin KV. Peripheral neuropathic pain syndromes. In: Batjer, HH, Loftus, CM, eds. *Textbook of Neurological Surgery*. Philadelphia: Lippincott Williams & Wilkins, 2003:3013-3022.
8. Long DM. The current status of electrical stimulation of the nervous system for the relief of chronic pain. *Surg Neurol* 1998;49:142-144.
9. Stanton-Hicks M, Salamon J. Stimulation of the central and peripheral nervous system for the control of pain. *J Clin Neurophysiol* 1997;14:46-62.
10. Melzack R, Wall PD. Pain mechanisms: a new theory. *Science* 1965;150:971-979.
11. Burchiel KJ, Slavin KV. On the natural history of trigeminal neuralgia. *Neurosurgery* 2000;46:152-155.
12. Meglio M. Percutaneously implantable chronic electrode for radiofrequency stimulation of the Gasserian ganglion: a perspective in the management of trigeminal pain. *Acta Neurochir (Wien)* 1984;33(Suppl.):521-525.
13. Meyerson BA, Håkansson S. Alleviation of atypical trigeminal pain by stimulation of the Gasserian ganglion via an implanted electrode. *Acta Neurochir (Wien)* 1980;30(Suppl.):303-309.
14. Holsheimer J. Electrical stimulation of the trigeminal tract in chronic, intractable facial neuralgia. *Arch Physiol Biochem* 2001;4:304-308.