

Peripheral Neurostimulation for Control of Intractable Occipital Neuralgia

Richard L. Weiner, MD, FACS* ■ Kenneth L. Reed, MD‡

*Departments of *Neurosurgery and ‡Anesthesiology, Presbyterian Hospital of Dallas, Dallas, Texas*

■ ABSTRACT

Objective. To present a novel approach for treatment of intractable occipital neuralgia using percutaneous peripheral nerve electrostimulation techniques.

Methods. Thirteen patients underwent 17 implant procedures for medically refractory occipital neuralgia. A subcutaneous electrode placed transversely at the level of C1 across the base of the occipital nerve trunk produced paresthesias and pain relief covering the regions of occipital nerve pain.

Results. With follow-up ranging from 1-½ to 6 years, 12 patients continue to report good to excellent response with greater than 50% pain control and requiring little or no additional medications. The 13th patient (first in the series) was subsequently explanted following symptom resolution.

Conclusions. In patients with medically intractable occipital neuralgia, peripheral nerve electrostimulation subcutaneously at the level of C1 appears to be a reasonable alternative to more invasive surgical procedures following failure of more conservative therapies. ■

KEY WORDS: occipital neuralgia, peripheral nerve stimulation, subcutaneous.

Occipital neuralgia is characterized by paroxysms of pain occurring within the distribution of the greater and/or lesser occipital nerves (1). The pain may radiate anteriorly to the ipsilateral frontal or retro-

orbital regions of the head. Extreme localized tenderness is often encountered upon palpation over the occipital notches with reproduction of focal and radiating pain. Though known causes include closed head injury, direct occipital nerve trauma, neuroma formation, or upper cervical root compression (spondylosis or ligamentous hypertrophy), most patients have no demonstrable lesion (1).

Treatment options for intractable occipital nerve pain refractory to medications usually involves chemical, thermal, or surgical ablation procedures following diagnostic local anesthetic blockade (2). Surgical approaches include neurolysis or nerve sectioning of either the peripheral nerve in the occipital scalp or at the upper cervical dorsal root exit zone (extradural). Foraminal decompression of C2 roots as well as C2 ganglionectomy have also been effective in selected cases (3-5).

Our experience with peripheral nerve electrical stimulation for painful mononeuropathies and complex regional pain syndromes involving one major peripheral nerve suggests that neuroaugmentation may be applicable to the peripheral occipital nerves. We report a new application of peripheral electrostimulation for the treatment of medically intractable occipital neuralgia.

MATERIALS AND METHODS

Thirteen adult patients (5 males, 8 females) underwent a total of 17 peripheral suboccipital subcutane-

Reprint requests to Richard L. Weiner, MD, Dallas Neurosurgical Associates, 8230 Walnut Hill Lane, Suite 220, Dallas, TX 75231.

ous implant procedures for intractable occipital neuralgia over a 6-year time interval (Table 1). Wire electrodes, including Pisces Quad, Quad Plus (Medtronic, Inc, Minneapolis, MN) and Octrode (Advanced Neuromodulation Systems (ANS), Inc, Plano, TX) arrays, were placed subcutaneously superficial to the cervical muscular fascia, transverse to the affected occipital nerve trunk at the level of C1 under fluoroscopic control. Totally implantable generators or RF receivers were pocketed subcutaneously either in the mid-axillary thoracic region or abdomen via anterior or posterior thoracic tunneling. Most patients had previously completed a successful 5–7 day trial outpatient stimulation with an externalized bipolar (Racz catheter) or quadripolar (Medtronic Pisces quad) electrode system. All patients had previously received treatment with diagnostic and therapeutic local anesthetic blocks into the region of the affected occipital nerve with initial benefit. Many patients also had some type of ablative treatment of the occipital nerve such as cryoprobe freezing or alcohol injections prior to referral for trial stimulation (Table 1). The three most recent patients in the series underwent permanent electrode placement without trial stimulation. Electrodes were attached to either total implant Itrel 2 or 3 generators (Medtronic), RF receivers (ANS), or dual matrix RF systems (Medtronic).

TRIAL STIMULATION

Outpatient percutaneous wire electrode insertion was accomplished with subcutaneous Tuohy needle placement transversely centered below the level of occipital tenderness in the upper cervical region. All wiring was secured to the skin with clear plastic dressings and attached to a temporary transmitter for a 5–7 day trial stimulation period. The electrode was completely removed at follow-up and patients were assessed for permanent PNS implant. The interview included a discussion regarding the patient's choice for implantation with an RF receiver or an IPG system (off-label use).

PERMANENT IMPLANT: OPERATIVE TECHNIQUE

Positioning

Most patients were positioned laterally to allow for electrode or extender wire tunneling medial to the scapula for flank, abdominal, or buttock receiver/generator pocketing (Fig. 1). The supine position with the head turned to the opposite side allows for anterior tunneling to the subclavicular or abdominal regions, however, care must be taken to avoid proximity of the extender wire connector to the carotid

Table 1. Occipital Neuralgia Patient Database

No	Pt	Age/Sex	Etiology	Implant	Device	F/U yrs	Prev procedures	Preop Sx	Outcome	Comments
1	JS	72/M	Idiopathic	4/92 12/92 7/93 3/96	PQ/Itrell II	4.0	Blocks Alcohol Cryoprobe	6 mo	Good	Revised Revised Explanted Sx resolved
2	NC	61/F	C. Spond	3/93 8/97	PQ/Itrell II	5.5	Blocks Facet Blocks	Long-term	Excellent	Revised
3	MH	60/F	Chi, AA	11/94 11/95	PQ/Itrell II	4.0	Blocks	2 yrs 2 yrs	Good Good	Right Left
4	DJ	40/F	C Sten	4/96	PQ/Itrell II	2.5	Blocks	Long-term	Good	5 volts req
5	BM	55/M	CHI, AA	5/96	PQ/Itrell III	2.5	Blocks, Cryo	6 mo	Excellent	
6	NL	51/F	Ear Infect.	7/96	PQ/Itrell III	2.5	Blocks, Cryo	6 mo	Excellent	
7	JT	26/M	CHI	3/97	PQ/Itrell III	1.5	Blocks, Cryo	2 yrs	Excellent	
8	WW	54/M	Idiopathic	4/97	Dual Matrix	1.5	Blocks	1 yr	Excellent	Bilateral
9	MA	35/M	CHI	5/97	PQ/Itrell III	1.5	Blocks, Cryo	4 yrs	Excellent	
10	JR	44/F	C Sten, AA	6/97	PQ/Itrell III	1.5	Blocks	1 yr	Excellent	
11	HH	56/F	Idiopathic	6/97	Octrode/RF	1.5	Blocks	5 yrs	Good	
12	WB	55/F	TMJ	6/97	Octrode/RF	1.5	C2 Rhiz	10 yrs	Excellent	
13	JC	59/F	Idiopathic	6/97	Dual Octrode/RF	1.5	C2 Rhiz	17 yrs	Good	

CHI, closed head injury; AA, auto accident; C Sten, cervical stenosis; C Spond, cervical spondylosis; TMJ, temporomandibular joint syndrome; PQ, Pisces Quad.

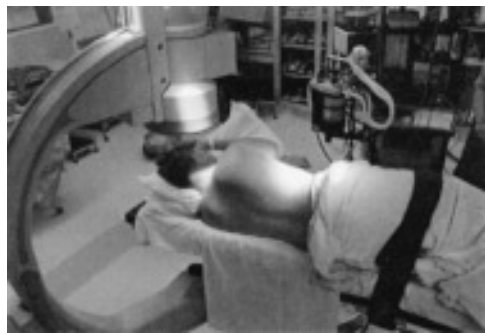

Figure 1. Lateral intraoperative positioning for thoracic or abdominal generator receiver placement

artery. This is easily solved with a longer wire electrode-connector array. The prone position may also be utilized with the head in a horseshoe frame or other suitable device.

Imaging

C-arm fluoroscopy was used to identify the C1 lamina landmark, which signifies the level of transverse electrode placement (Fig. 2).

Procedure

Using local anesthesia a 2-cm vertical skin incision is made at the level of C1 lamina either medial and inferior to the mastoid process or in the midline posteriorly. The subcutaneous tissues immediately lateral to the incision are undermined with sharp scissors to accept a loop of wire electrode created after placement and tunneling to prevent electrode migration. A Tuohy needle is gently curved to conform to the transverse cervical curvature (bevel in-

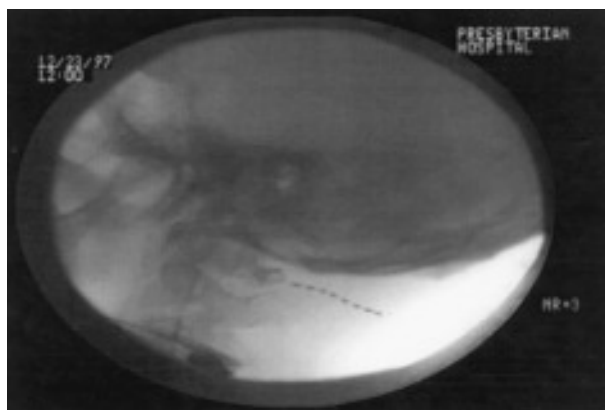


Figure 2. Subcutaneous electrode placement at C1 level

wards) and without further dissection is passed transversely in the subcutaneous space across the base of the affected greater and/or lesser occipital nerves which at the level of C1 are located within the cervical musculature and overlying fascia (Fig. 3). Single or dual quadripolar as well as single or dual octopolar electrodes may be passed from a midline incision to either affected side or alternatively placed to traverse the entire cervical curvature bilaterally from a single side. Rapid needle insertion usually obviates the need for even a short acting general anesthetic. Following placement of the electrode into the Tuohy needle (Fig. 4), the needle is withdrawn and the electrode connected to an extender cable for intraoperative testing (Fig. 5). Stimulation is then applied using a temporary RF transmitter to various select electrode combinations, enabling the patient to report stimulation location, intensity, and overall sensation.

Almost all patients have reported immediate stimulation in the selected occipital nerve distribution with voltage setting usually below 2 V. A report of burning pain or muscle pulling should alert the surgeon the electrode is probably placed either too close to the fascia or too far above or below the C1 level and should be repositioned more superficially in the subcutaneous space by removal and reinsertion of the needle and electrode. Repeated needle passage for electrode placement should be avoided

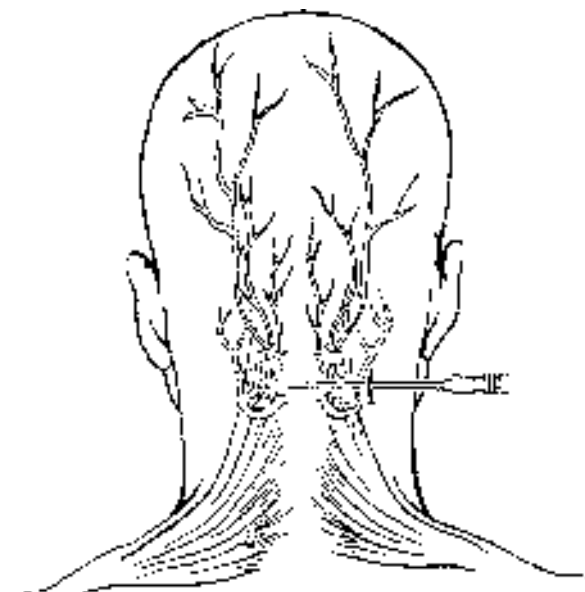


Figure 3. Tuohy needle placement at C1 level

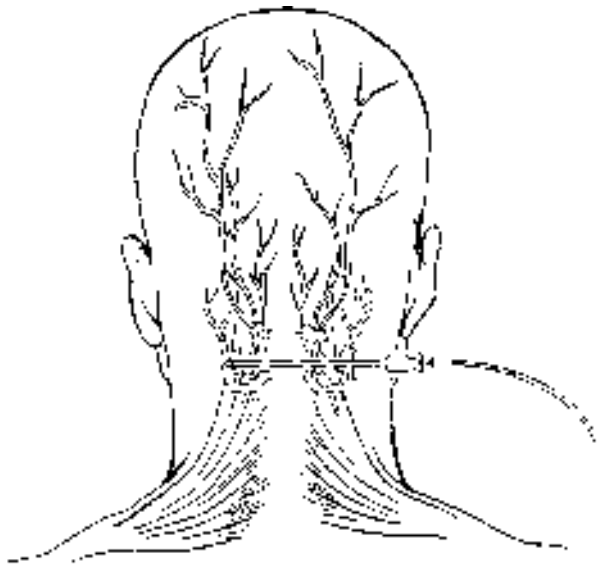


Figure 4. Electrode placement

to reduce the risk of subcutaneous edema and/or hematoma formation which can result in loss of electrode conductivity. Following successful stimulation the electrode is sutured to the underlying fascia with the supplied silicone fastener and 2-0 silk suture. A loop of electrode is also sutured in place to reduce the risk of electrode migration (Fig. 6). A short acting general anesthetic is used to tunnel the electrodes or extender wire to the distal site

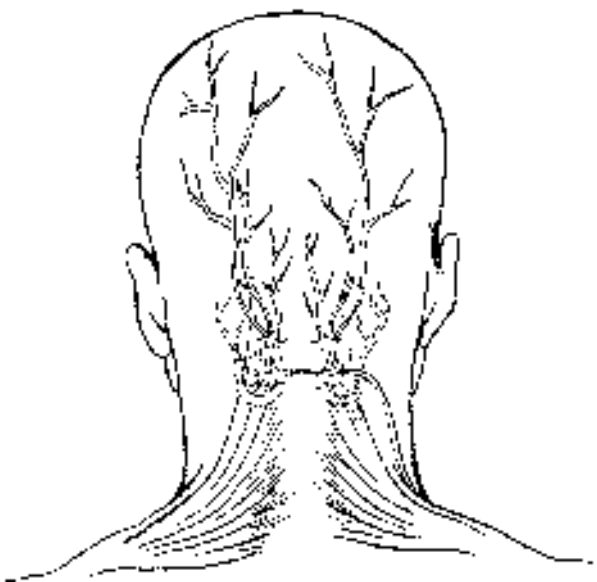


Figure 5. Electrode in position for stimulation



Figure 6. Lead anchored to fascia with electrode loop to prevent migration

for connection and implantation of the receiver/generator. Typical stimulator parameters include pulse widths of 90-180 μ s, frequency 60-130 Hz, and power of 0.5-2 V. Higher rates of up to 400 Hz with radio frequency systems have also been beneficial.

RESULTS

Thirteen patients underwent 17 implant procedures for treatment of unilateral or bilateral intractable occipital neuralgia over a period of 6 years. One patient (NC) required a new electrode (Pisces Quad Plus, Medtronic) from the opposite side of initial placement after the first electrode was severed and became infected during removal of an overlying skin growth performed elsewhere. The first implant patient (JS) was revised 8 months after implantation because of lead migration. The electrode was subsequently removed at the patient's request, then reimplanted for recurrent pain. The device was explanted 3 years later following resolution of occipital neuralgia symptoms. Patient MH underwent separate right and left lead and generator implants over a one-year interval.

Follow-up for the remaining 12 patients ranges from one to 6 years averaging over 2 years. Two-thirds of the patients have had excellent responses (greater than 75% pain relief) and one-third have had a good response (greater than 50% pain relief) requiring little or no additional medications (Table 1). A few patients have reported using the device to abort paroxysms of radiating occiput to retro-orbital pain, which seems to define the neuralgia at its most debilitating state.

DISCUSSION

The incidence of potentially treatable occipital neuralgia can approach 50% in patients otherwise diagnosed as suffering from migraines (6). Headaches that respond to injections of local anesthetic with or without steroids into the greater or lesser occipital nerves must be differentiated from cervicogenic or migraine pain. The patients in our series uniformly responded to local occipital nerve or selective C2 root block injections at least initially, though several became refractory with time.

The greater occipital nerve is derived as the medial branch of the posterior C2 and C3 primary sensory divisions of the cervical nerves along with the lesser occipital nerve (C3) and emerges between the posterior arch of C1 and the lamina of C2 ascending and piercing the semispinalis and trapezius muscles near their attachment on the occipital skull medial to the occipital artery. These nerves supply the posterior scalp over the vertex via the superficial fascia (7,8).

The transverse subcutaneous placement of a wire type quadripolar or octopolar electrode to treat occipital neuralgia represents a departure from the usual spinal cord and peripheral nerve stimulation techniques. Early observations during surgery for peripheral nerve flat paddle electrode placement revealed that a variety of structures, including fascia and subcutaneous tissue not immediately adjacent to the major peripheral nerve, could be induced to produce adequate paresthesias into the affected limb with wire electrodes in a myotomal as well as dermatomal distribution.

CONCLUSIONS

Subcutaneous peripheral neurostimulation in the region of one or more occipital nerves represents a new application of PNS neuroaugmentation for

control of refractory occipital nerve mediated pain. The long-term efficacy of occipital nerve stimulation requires further study; however, our experience over the past 6 years suggests this relatively simple technique is quite effective in controlling severe pain from otherwise medically intractable occipital neuralgia.

REFERENCES

1. Ziegler DK, Murrow RW. Headache. In: Joynt R, ed. *Clinical Neurology*, Vol. 2, Philadelphia: JB Lippincott, 1988, pp. 1-35.
2. Stechison MT, Mullin BB. Surgical treatment of greater occipital neuralgia: an appraisal of strategies. *Acta Neurochir (Wien)* 1994;131:236-240.
3. Poletti CE, Sweet WH. Entrapment of the C2 root and ganglion by the atlanto-epistrophic ligament: Clinical syndrome and surgical anatomy. *Neurosurgery* 1990;27:288-291.
4. Poletti CE. Proposed operation for occipital neuralgia: C-2 and C-3 root decompression. *Neurosurgery* 1983;12:221-224.
5. Dubuisson D. Treatment of occipital neuralgia by partial posterior rhizotomy at C1-3. *J Neurosurg* 1995;82:581-586.
6. Anthony M. Headache and the greater occipital nerve. *Clin Neurol Neurosurg* 1992;94:297-300.
7. Groen GJ, Baljet B, Drukker J. Nerves and nerve plexuses of the human vertebral column. *Am J Anat* 1990;188:282-296.
8. Becser N, Bovim G, Sjaastad O. Extracranial nerves in the posterior part of the head: anatomic variations and their possible clinical significance. *Spine* 1998;23:1435-1441.