

# Peripheral Neurostimulation for the Treatment of Refractory Cluster Headache, Long-Term Follow-Up: Case Report

Antonios Mammis, MD\*<sup>†</sup>, Mark Gudesblatt, MD<sup>‡</sup>, Alon Y. Mogilner, MD, PhD\*

**Introduction:** Cluster headache is a headache syndrome characterized by periodic episodes of intense headache with spontaneous remission. There are recent reports utilizing occipital nerve stimulation for the successful management of medically refractory cases of cluster headache.

**Methods:** The case of an 18-year-old boy with chronic, refractory, recurrent cluster headaches is presented. He was treated surgically with combined occipital, supraorbital, and infraorbital nerve stimulation.

**Results:** Prior to operation, the patient suffered three to four episodes of cluster headache per day, for four years. After implantation of occipital, supraorbital, and infraorbital nerve stimulators, the patient averages at most three to four headaches per month, at 36-month follow-up.

**Conclusion:** Peripheral neurostimulation is safe and efficacious in the management of chronic, medically refractory cluster headache syndrome. The efficacy of treatment was found to be persistent after three years.

**Keywords:** Cluster headache, occipital nerve stimulation, peripheral neurostimulation

**Conflict of Interest:** Dr. Mogilner receives consulting fees and grant support from Medtronic. Dr. Mammis receives grant support from Medtronic. Dr. Gudesblatt receives consulting fees from Medtronic.

## INTRODUCTION

Cluster headache is a syndrome characterized by periodic episodes of intense unilateral head pain of variable duration and typically followed by spontaneous remission (1,2). The prevalence of cluster headache is 0.1%, and men are typically affected more than women (3). Cluster headaches may occur as episodic clusters or in a chronic form. The episodic type typically has at least two clusters varying from one week to one year separated by cluster-free intervals of one month or longer. The chronic form can have clusters occurring more than yearly, with no remission (4). Approximately 1% of all chronic cluster headaches become refractory to standard medical therapy (5). The pathophysiology of cluster headache is unclear, with some investigators concluding that this is a centrally mediated process, while others a peripheral process (6). Studies using functional neuroimaging, to investigate the cause of cluster headache, have implicated posterior hypothalamic involvement (7,8).

The traditional management of cluster headache has comprised a number of medical strategies, for both abortive and prophylactic treatment. Acute treatment includes oxygen inhalation, subcutaneous sumatriptan, oral ergotamine, and the nasal application of lidocaine. Pharmacologic strategies for the prevention of cluster headaches include oral doses of verapamil, lithium, methysergide, pizotifen, topiramate, or melatonin and intranasal capsaicin (9–13).

In cases that are refractory to maximal medical management, surgical options can be explored. Surgical procedures that have been done for cluster headache include microvascular decompression, trigeminal glycerol or radiofrequency rhizotomy, gamma knife surgery to the trigeminal nerve and/or sphenopalatine ganglion,

sectioning of the nervus intermedius or greater superficial petrosal nerve, or sphenopalatine ganglion lesioning or blockade (11,14–16). Ansarinia et al. described a technique of electrical stimulation of the sphenopalatine ganglion for acute treatment of cluster headaches (17). Deep brain stimulation of the posterior hypothalamus for the treatment of cluster headache also has been reported (18–20). Recently, various peripheral neurostimulation techniques, including occipital and supraorbital nerve stimulation, have been tried for the management of refractory cluster headache (21–24). We present a case of an 18-year-old boy with refractory cluster headache syndrome, who, at 36-month follow-up, demonstrated significant benefit after combined occipital, supraorbital, and infraorbital nerve stimulation.

Address correspondence to: Alon Y. Mogilner, MD, PhD, 865 Northern Boulevard, Suite 201, Great Neck, NY 11021, USA. Email: amogilner@nshs.edu

\* Department of Neurosurgery, Cushing Neuroscience Institutes, Hofstra University School of Medicine and North Shore University Hospital, Manhasset, New York, USA;

<sup>†</sup> Department of Neurological Surgery, UMDNJ—New Jersey Medical School, Newark, New Jersey, USA; and

<sup>‡</sup> South Shore Neurologic Associates, Bay Shore, New York, USA

For more information on author guidelines, an explanation of our peer review process, and conflict of interest informed consent policies, please go to <http://www.wiley.com/bw/submit.asp?ref=1094-7159&site=1>

## CASE DESCRIPTION

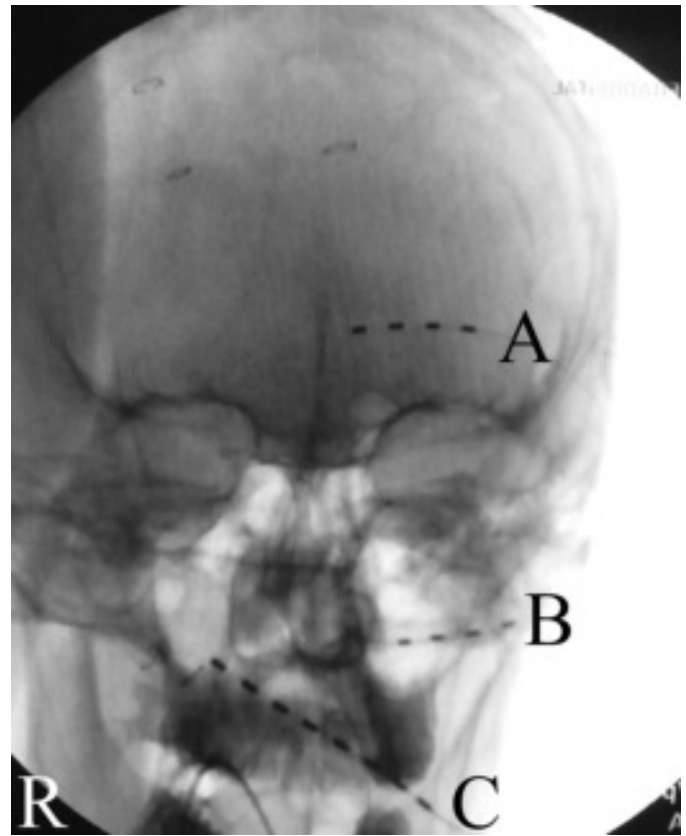
The patient is an 18-year-old left handed male with a more than four-year history of almost daily unremitting cluster headache. He described episodic left periorbital pain associated with injection and redness of the eye, tearing, drooping of the eyelid, and rhinorrhea. The episodes occurred three to four times a day and lasted for approximately two hours. There was no additional past medical, surgical, or family history. His general medical and neurologic exams were normal on multiple occasions.

Over the course of four years, he had been treated with sumatriptan injections, frovatriptan, almotriptan, eletriptan, divalproex, verapamil, propranolol, naproxen, amitriptyline, and topiramate with minimal improvement in his condition. He also had used supplemental high flow oxygen, with some temporal reduction of headaches. The addition of methylergonovine and prednisone helped him achieve his first four-week headache-free period, but he developed severe leg cramping. The decision was then made to discuss a trial of peripheral neurostimulation with the patient. Prior to the procedure, both occipital nerve as well as trigeminal branch (supra- and infraorbital) stimulation were discussed. Given the more extensively published data utilizing occipital nerve stimulation to treat cluster headache, the decision was made to perform an occipital nerve stimulator trial, with the possibility left open that trigeminal branch stimulation could be attempted at a later date.

A percutaneous left occipital stimulator trial was performed using standard surgical technique. The patient was positioned supine, with the head turned towards the right. After infiltration with local anesthetic, a curved spinal needle was advanced subcutaneously from the left retromastoid region towards the radiographic projection of the tip of the odontoid process at the level of the C1 arch. An eight-pole spinal cord stimulating electrode (Model 3778, Medtronic, Inc., Minneapolis, MN, USA) was advanced through the needle, under fluoroscopic guidance. After removing the stylette and needle under fluoroscopic guidance, the lead was sutured to the skin with a plastic anchor and 2-0 silk ties. The patient was then taken to the recovery room, where his outpatient trial of stimulation began.

The patient reported a significant reduction in the frequency and severity of his headaches during the five-day trial period, and proceeded to permanent implantation under general anesthesia. The patient returned with the occipital lead still in place. At the start of the case, a fluoroscopic image was taken of the lead location, and the lead was then removed prior to prepping and draping. A new lead was then placed in the identical location, and a linear incision was made over the needle entry point in the retromastoid region, where the lead was anchored to the fascia with a plastic anchor (Titan, Medtronic, Inc.) and multiple 2-0 silk ties. A subcutaneous pocket was then fashioned in the infraclavicular region, and the electrode was tunneled down and connected to an implantable pulse generator (Restore Ultra Model 37712, Medtronic, Inc.). The patient was discharged home that same day.

Upon postsurgical follow-up at eight weeks' time, the patient reported less than 50% reduction in his headaches, with persistent orbital pain. Given the lack of pain relief, the decision was made to add trigeminal branch stimulating electrodes to the system. He was then taken back to the operating room for placement of left supraorbital and infraorbital stimulating electrodes, under general anesthesia. Using techniques similar to those described above, two quadripolar stimulating electrodes (Pisces Quad Model 3487A-45, Medtronic, Inc.) were introduced with curved spinal needles from a



**Figure 1.** Intraoperative anterior-posterior skull radiograph, demonstrating the positions of the supraorbital (A), infraorbital (B), and occipital (C) neurostimulation leads.

temporal incision towards the supraorbital and infraorbital regions. Placement was confirmed fluoroscopically (Fig. 1). The leads were tunneled to a point 2 cm above and 3 cm posterior to the pinna, where a curvilinear incision was made down to the temporalis fascia, where the leads were anchored and connected via a bifurcated extension (Model 3708260, Medtronic, Inc.) to the pulse generator in the previously unused second channel.

At four-month follow-up, the patient was headache-free and his pre-stimulator medication schedule and doses were significantly reduced. At 16-month follow-up, the patient remained headache-free and was relying only on amitriptyline monotherapy, which represented his first prolonged headache-free period in years. At 22-month follow-up, he reported only a single headache associated with the ingestion of monosodium glutamate. At 36-month follow-up, the patient reported at most three to four headaches per month, which were brief, isolated, and responsive to triptan therapy. The cluster headaches were no longer daily, persistent, or frequently recurring, at last visit. The patient reported dramatic improvement in his perception of quality of life.

At 36-month follow-up, the patient's programming parameters remained almost identical to those he had been using since the implantation of the supraorbital and infraorbital leads. The four-pole supraorbital stimulator's 1-, 3+ contacts were actively in use, with an amplitude of 0.8 V, pulse width of 90  $\mu$ sec, and with a rate of 60 Hz. The four-pole infraorbital stimulator's 5+, 7- contacts were actively in use, with an amplitude of 1.65 V, pulse width of 90  $\mu$ sec and with a rate of 60 Hz. Finally, the eight-pole occipital stimulator's 10+, 11-, 12+, 13-, 14-, 15- contacts were actively in use, with an

amplitude of 3.15 V, pulse width of 800  $\mu$ sec, and with a rate of 60 Hz.

## DISCUSSION

Available literature on the use of peripheral neurostimulation for headache includes occipital nerve stimulation, supraorbital nerve stimulation, and infraorbital nerve stimulation. Occipital nerve stimulation is by far the most commonly performed of the three (21,22,25,26).

There are a few reported studies of peripheral neurostimulation for medically intractable cluster headache. Goadsby reported eight patients who underwent implantation of occipital nerve stimulators, with a median follow-up period of 20 months. He described two patients with substantial improvement, three with moderate, and one with mild improvement (16). In a subsequent report, the same investigators described 14 patients who were treated with bilateral occipital nerve stimulation were followed for a median period of 17.5 months. Three patients described marked improvement, three described moderate, and four had mild improvement in headaches (27).

Magis reported on eight patients with intractable cluster headache, who were treated with unilateral occipital nerve stimulation. At a mean follow-up of 15.1 months, two patients were headache-free, three reported a 90% frequency reduction, and two had a 40% reduction (28). De Quintana-Schmidt described four patients who had occipital nerve stimulators placed for medically intractable cluster headache. At six-month follow-up, there was a 56% reduction in headache frequency, 48.8% reduction in intensity, and 63.8% reduction in duration. Furthermore, three out of the four patients had a significant reduction in their medications and all patients reported improvement in their quality of life (29).

While there have been reports of using combined occipital and supraorbital neurostimulation for migraine headache, there is a paucity of literature on cluster headache (30). Narouze reported on a case of supraorbital nerve stimulation alone being used successfully for chronic cluster headache (31). There are no reports or studies of infraorbital stimulation for cluster headache.

This report represents the first description of combined occipital nerve, supraorbital nerve, and infraorbital nerve stimulation for the treatment of intractable cluster headache. It is important to note that our patient required and continues to utilize all three contacts to achieve >50% pain relief. It should be noted that Magis and colleagues reported a delay in efficacy of at least two months between occipital lead implant and pain relief in their series (28). In our patient, the trigeminal branch stimulators were implanted ten weeks following the occipital lead due to persistent headaches. It is possible that pain relief would have been obtained with only the occipital lead had we waited longer prior to trigeminal branch stimulator placement. However, without a rigorous washout process of activating each lead independently and re-assessing the patient, we cannot state this with absolute certainty. At this point in time, given his dramatic clinical improvement on the current settings, we do not consider it ethical to attempt such an assessment.

This is the only report documenting a significant role of infraorbital stimulation, in conjunction with occipital and supraorbital, for cluster headache. One could speculate that the use of combination peripheral neurostimulation, in cases of medically refractory cluster headache, may promote greater levels of pain relief. The clinical observation follow-up of 36 months also is among the longest

described in the literature for any means of peripheral neurostimulation for cluster headache.

## CONCLUSION

Peripheral neurostimulation can be used for the management of chronic, medically refractory cluster headache syndrome. In this case report, our patient was able to significantly reduce his headache frequency and intensity. Furthermore, he was able to reduce his medication regimen. The dramatic efficacy of treatment was found to be persistent at 36-month follow-up.

## Acknowledgements

The authors would like to acknowledge the contribution of Cliff Miller, RN, NP, South Shore Neurologic Associates, who was involved in the postoperative programming and maintenance of the neurostimulator.

## Authorship Statements

A. Mammis prepared the manuscript draft. M. Gudesblatt conceived the manuscript and reviewed the draft. A. Mogilner reviewed the draft. All authors approved the submitted version of the manuscript.

## How to Cite this Article:

Mammis A., Gudesblatt M., Mogilner A.Y. 2011. Peripheral Neurostimulation for the Treatment of Refractory Cluster Headache, Long-Term Follow-Up: Case Report. *Neuromodulation* 2011; 14: 432–435

## REFERENCES

- Goadsby PJ. Pathophysiology of cluster headache: a trigeminal autonomic cephalgia. *Lancet Neurol* 2002;1:37–43.
- Capobianco DJ, Dodick DW. Diagnosis and treatment of cluster headache. *Semin Neurol* 2006;26:242–259.
- Bahra A, May A, Goadsby PJ. Cluster headache: a prospective clinical study with diagnostic implications. *Neurology* 2002;58:354–361.
- Dodick DW, Rozen TD, Goadsby PJ, Silberstein SD. Cluster headache. *Cephalalgia* 2000;20:787–803.
- Magis D, Schoenen J. Neurostimulation in chronic cluster headache. *Curr Pain Headache Rep* 2008;12:145–153.
- Leone M, Bussone G. Pathophysiology of trigeminal autonomic cephalgias. *Lancet Neurol* 2009;8:755–764.
- May A, Bahra A, Buchel C, Frackowiak RS, Goadsby PJ. PET and MRI findings in cluster headache and MRA in experimental pain. *Neurology* 2000;55:1328–1335.
- DaSilva AF, Goadsby PJ, Borsook D. Cluster headache: a review of neuroimaging findings. *Curr Pain Headache Rep* 2007;11:131–136.
- Matharu MS, Boes CJ, Goadsby PJ. Management of trigeminal autonomic cephalgias and hemicrania continua. *Drugs* 2003;63:1637–1677.
- Matharu MS, Goadsby PJ. Cluster headache: a review with a focus on emerging therapies. *Expert Rev Neurother* 2004;4:895–907.
- May A. Cluster headache: pathogenesis, diagnosis, and management. *Lancet* 2005;366:843–855.
- Leone M, Franzini A, Cecchini AP, Mea E, Broggi G, Bussone G. Management of chronic cluster headache. *Curr Treat Options Neurol* 2011;13:56–70.
- Leone M, Franzini A, Cecchini AP, Mea E, Broggi G, Bussone G. Cluster headache: pharmacologic treatment and neurostimulation. *Nat Clin Pract Neurol* 2009;5:153–162.
- Kano H, Kondziolka D, Mathieu D et al. Stereotactic radiosurgery for intractable cluster headache: an initial report from the North American Gamma Knife Consortium. *J Neurosurg* 2010;114(6):1736–1743. published online April 30, 2010; DOI: 10.3171/2010.3.JNS09184.
- Levin M. Nerve blocks in the treatment of headache. *Neurotherapeutics* 2010;7:197–203.

16. Burns B, Watkins L, Goadsby PJ. Treatment of medically intractable cluster headache by occipital nerve stimulation: long-term follow-up of eight patients. *Lancet* 2007;369:1099–1106.
17. Ansarinia M, Rezaei A, Tepper SJ et al. Electrical stimulation of sphenopalatine ganglion for acute treatment of cluster headaches. *Headache* 2010;50:1164–1174.
18. Leone M, Franzini A, Cecchini AP, Broggi G, Bussone G. Hypothalamic deep brain stimulation in the treatment of chronic cluster headache. *Ther Adv Neurol Disord* 2010;3:187–195.
19. Hidding U, May A. Mere surgery will not cure cluster headache—implications for neurostimulation. *Cephalalgia* 2010;31:112–115.
20. Franzini A, Messina G, Cordella R, Marras C, Broggi G. Deep brain stimulation of the posteromedial hypothalamus: indications, long-term results, and neurophysiological considerations. *Neurosurg Focus* 2010;29:E13.
21. Dafer RM. Neurostimulation in headache disorders. *Neurol Clin* 2010;28:835–841.
22. Schoenen J, Allena M, Magis D. Neurostimulation therapy in intractable headaches. *Handb Clin Neurol* 2010;97:443–450.
23. Bartsch T, Paemeleire K, Goadsby PJ. Neurostimulation approaches to primary headache disorders. *Curr Opin Neurol* 2009;22:262–268.
24. Schwedt TJ. Neurostimulation for primary headache disorders. *Curr Neurol Neurosci Rep* 2009;9:101–107.
25. Weiner RL, Reed KL. Peripheral neurostimulation for control of intractable occipital neuralgia. *Neuromodulation* 1999;2:217–221.
26. Slavin KV, Wess C. Trigeminal branch stimulation for intractable neuropathic pain: technical note. *Neuromodulation* 2005;8:7–13.
27. Burns B, Watkins L, Goadsby PJ. Treatment of intractable chronic cluster headaches by occipital nerve stimulation in 14 patients. *Neurology* 2009;72:341–345.
28. Magis D, Allena M, Bolla M, De Pasqua V, Remacle JM, Schoenen J. Occipital nerve stimulation for drug-resistant chronic cluster headache: a prospective pilot study. *Lancet Neurol* 2007;6:314–321.
29. de Quintana-Schmidt C, Casajuana-Garreta E, Molet-Teixido J et al. Stimulation of the occipital nerve in the treatment of drug resistant cluster headache. *Rev Neurol* 2010;51:19–26.
30. Reed KL, Black SB, Banta CJ 2nd, Will KR. Combined occipital and supraorbital neurostimulation for the treatment of chronic migraine headaches: initial experience. *Cephalalgia* 2009;30:260–271.
31. Narouze SN, Kapural L. Supraorbital nerve electric stimulation for the treatment of intractable chronic cluster headache: a case report. *Headache* 2007;47:1100–1102.

## COMMENTS

Chronic cluster headache can be one of the most disabling primary headache disorders. New treatment modalities are needed for refractory cases. Peripheral nerve stimulation may provide relief when medications, injections and other therapies fail. The authors present an interesting case of multiple peripheral nerve stimulation (occipital, supraorbital and infraorbital) that provided long term benefit. This case supports the contention that further studies of peripheral nerve stimulation for headache disorders are indicated.

Terrence L. Trentman, MD  
Scottsdale, AZ USA

\*\*\*

Cluster headache (CH) is a rare but extremely disabling medical condition. Due to frequent ineffectiveness of medical treatment, multiple surgical approaches have been proposed including both destruction (such as radiosurgical ablation of sphenopalatine ganglion (SPG)) and neuromodulation, including hypothalamic deep brain stimulation (DBS). The less invasive alternatives of occipital or, more recently, supraorbital peripheral nerve stimulation (PNS) have also been described.

The novel concept of Dr. Mogilner and his colleagues involve combination of previously described approach with addition of infraorbital nerve stimulation component. This is quite intuitive PNS application considering periorbital location of painful attacks and therefore its success is not surprising.

Following the concept of CH being a trigeminal autonomic dysfunction, the final question however, will remain until some kind of randomized study is performed: is there any benefit in stimulating area where the pain is located (as described in this case report) vs. more central location from where pain may be originating (assuming that CH is a malfunction of SPG), vs. the brain area where the pain is processed (i.e., hypothalamus)?

A point worth emphasizing in this particular case report is that best clinical results are obtained when individualized patient-based approach is combined with the spirit of innovation.

Konstantin V. Slavin, MD, FAANS  
Chicago, IL USA

\*\*\*

Interesting case report in a field of increasing interest involving headache, peripheral-cranial nerves and central neuromodulation. Unfortunately, the figure is not explicative of the surgical technique and may have the result of misleading readers with respect to leads connections and location. I might suggest an "artist drawing" of the definitive implant or a schematic drawing of the connections.

Angelo Franzini, MD  
Milan, Italy

Comments not included in the Early View version of this paper.