

Occipital Nerve Stimulation for the Treatment of Chronic Cluster Headache – Lessons Learned from 18 Months Experience

Authors

O. M. Mueller¹, C. Gaul², Z. Katsarava², H. C. Diener², U. Sure¹, T. Gasser¹

Affiliations

¹ University Hospital Essen, Neurosurgery, Essen, Germany

² University Hospital Essen, Neurology, Essen, Germany

Key words

- chronic cluster headache
- occipital nerve stimulation
- neuromodulation

Abstract



Objective: Neuromodulation has been recognized as a valuable surgical treatment option for patients with refractory chronic cluster headache (CCH). Due to the small number of afflicted individuals, the knowledge about this specific therapy is limited. In this study, we present our experiences with bilateral occipital nerve stimulation (ONS) in patients with CCH focusing on patient selection, pre- and postoperative evaluation, surgical procedures, and outcome.

Patients and Methods: Since December 2008, 10 patients with CCH have been treated with ONS at our department. Patients were recruited and clinically followed by a neurologist and a neurosurgeon. Baseline data records on frequency, intensity, and duration of attacks as well as the use of medication were assessed with a 30-day diary. Standardized questionnaires were used pre- and postoperatively and during the follow-up on a regular basis. Surgical procedure and stimulation parameters were standardized for all patients. Lead implantation was followed by a test period of 30 days prior to implantation of the permanent generator. Mean follow-up time was 12 months (range 3–18).

Results: All patients responded to the stimulation treatment. Frequency, duration, and severity of the cluster attacks were reduced in 90% of the patients. One patient had a significant reduction of his concomitant tension headache. 70% of the patients needed less medication during the attacks. All patients reported an improvement in their quality of life. The SF-36 showed a tendency toward objective improvement in the field of psychological comfort. As a major adverse event, one generator had to be exchanged due to a local infection. Another patient had to be reoperated due to a scar tissue formation around the thoracic connector.

Conclusions: ONS is a valuable tool in the treatment of patients with refractory CCH. According to our data, the potential side effects and complication rates of the operation are small. With a meticulous selection of patients by an interdisciplinary team, CCH can be improved in the majority of the patients. Yet, the optimal parameters for the stimulation regarding pulse width and frequency remain unclear. For this reason, we started a prospective single-center observational trial at our center in October 2009, including patients with ONS, to identify the best stimulation parameters.

Bibliography

DOI <http://dx.doi.org/10.1055/s-0030-1270476>

Published ahead of print:

29 March 2011

Cen Eur Neurosurg 2011;

72: 84–89

© Georg Thieme Verlag KG

Stuttgart · New York

ISSN 1868-4904

Correspondence

Dr. O. M. Mueller

University Hospital Essen

Neurosurgery

Hufelandstraße 22

45122 Essen

Germany

Tel.: +49/201/723 1204

Fax: +49/201/723 5909

Oliver.mueller@uk-essen.de

Introduction



Cluster headache (CH) is a rare but disabling disorder with a prevalence of 0.05–0.1% and a male preponderance of 3:1 [1]. CH belongs to the group of trigemino-autonomic headaches and is characterized by multiple daily attacks that last between 15 and 180 min. Symptoms like lacrimation, conjunctival injection, ptosis, miosis, and rhinorrhea of the same site are typically associated with the attacks. In contrast to migraine attacks, cluster patients show restlessness during attacks. The attacks commonly appear in a circadian rhythm at night and culminate in spring and autumn, suggestive of an underlying semestral cycle. The pathophysiology of CH is only partly understood. Recent data suggest a causative role of the hypothalamus (the circadian rhythm) and the trigeminal and cranial autonomic system (parasympathetic fibers of the 7th cranial nerve). A familial accumulation occurs in 7% of the cases with a 14-fold increased risk among first-degree relatives [2].

CH is diagnosed solely by clinical criteria [3]. In more than 80% of the patients, the episodic character of the cluster headache persists for more

than a decade. In about 12% of these patients, episodic CH converts to chronic cluster headache (CCH). A chronic cluster headache is defined as an all-season disease with attack-free intervals of less than a month [3].

During the attack, triptans (subcutaneously or endonasally applied) and oxygen (inhaled via a tight mask) are the first-choice therapeutic agents [4–6]. Long-term preventive therapy is performed with verapamil (a calcium channel blocker), lithium, or topiramate. Thereby, it is often necessary to combine these drugs and high doses may be required. The side effects of the drugs in high concentrations are often a limiting factor. Despite this, some patients will not be able to cope with the attacks even though they take preventive medications in a maximal dose [7,8]. CCH will be regarded as refractory if the substances mentioned above, alone or in combination, will not lead to a sufficient reduction of the number or severity of attacks [9]. Neuromodulation has gained wide attention for the treatment of CCH during the past decade. Deep brain stimulation (DBS) of the posterior hypothalamus has been employed in a small number of patients that have CCH with impressive results [10]. Initially, a reduction of frequency and intensity of the attacks of up to 70% and pain-free intervals of weeks were reported in the literature. Later on, the promising results of the first series could not be reproduced and, furthermore, severe adverse events led to a more restricted use of DBS [11, 12].

Burns et al. were the first to report the successful application of ONS in CCH patients, originally introduced by Weiner and Reed in 1999 for the treatment of occipital neuralgia [13, 14]. In their series of 14 patients, pain relief and reduction of attacks was reported to be between 20–90%. Procedure-associated complications included lead migration and dislocation of the electrodes, and local infections. Overall, the procedure proved to be safer than DBS [15]. Yet, no prospective or controlled randomized trials showed the efficacy of the ONS.

We report our experiences with 10 patients treated at our department since December 2008. To evaluate the mechanism of ONS and identify effective stimulation parameters, all patients were operated according to a standardized protocol. Stimulation parameters were equal in all patients with a fixed pulse width and frequency. The study protocol was approved by the local research ethics board (09-4143).

Patients and Methods



Recruitment and presurgical evaluation

Since December 2008, 10 patients were treated with ONS for intractable CCH. All patients were initially seen by a neurologist (CG, ZK, HCD) and suggested for ONS, if their CCH was considered refractory. The cluster headache was defined as being refractory when the attacks were not controlled by acute or preventive medication (verapamil ≥ 450 mg/d, topiramate ≥ 150 mg/d, lithium plasma level within therapeutic range, drugs alone or in combination).

To establish a prospective data baseline for the frequency and intensity of the cluster attacks, use of medication and/or oxygen, and preventive medication, patients were asked to keep a diary throughout a 30-day period before lead implantation. Contrast-enhanced magnetic resonance imaging (MRI) of the cranium was performed prior to surgery to rule out any intracranial pathology. Pain scores (numeric rating scale/NRS) and a standard questionnaire for the assessment of life quality (SF-36) were ascertained.

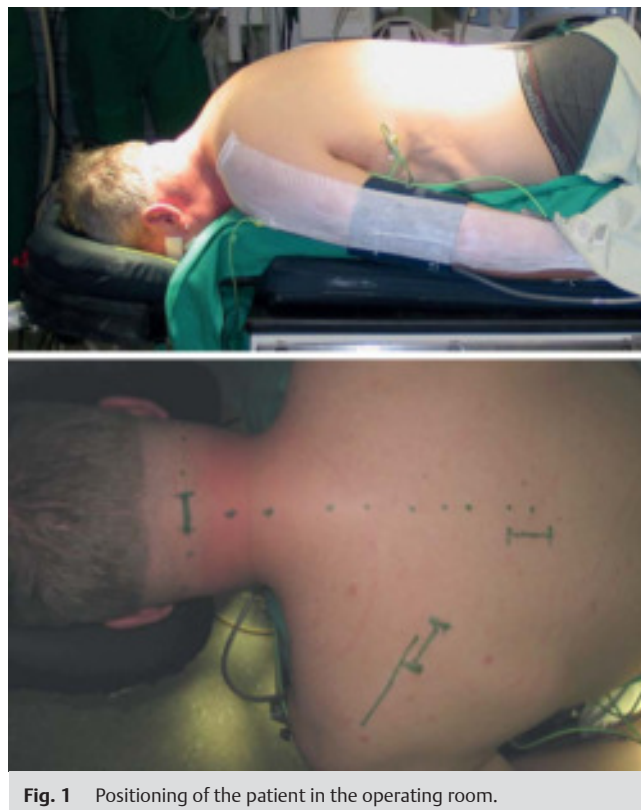

Fig. 1 Positioning of the patient in the operating room.

Patients were informed about the operation and the non-standard use of the electrodes and generator for this affliction. Informed consent for surgery and the participation in the study were obtained.

There were 2 women and 8 men (mean age 39 years; range 18–54 years) with a medical history of CCH of 8 years on average (range 2–20 years). One patient had a primary onset of CCH without a preceding episodic cluster. Mean follow-up time was 12 months (range 3–18 months).

All scores analyzed in this report represent a cross-sectional survey of our patients in May 2010, regardless of their performance at that time.

Operation I – placement of the electrodes

The patients were operated under standardized conditions by 2 neurosurgeons (OMM, TG). Surgery was done under general anesthesia with the patient in the prone position. The head was placed on moulded cushions, and slightly inclined to flatten the neck. Sterile drapes covered the operation field from the external protuberance down to the left flank (◉ Fig. 1).

The skin was incised a fingers width beneath the occiput. We preferred a horizontal incision of 3 cm length, as this proved to be more comfortable when preparing a small subcutaneous pouch in order to place the loops of the leads. The pouch was prepared down to the superficial fascia of the neck, where the leads were secured with a non-resorbable suture. From the horizontal cut, a Touhy needle was bilaterally advanced subcutaneously towards the mastoid process. We have learned from the literature and observed in our own series that CH might change site after stimulation. Therefore, it is compulsory to perform ONS bilaterally, a point about which the patients have to be informed prior to surgery.

The course of the needle should not be too superficial, which may cause local discomfort, especially in slim individuals. Fur-

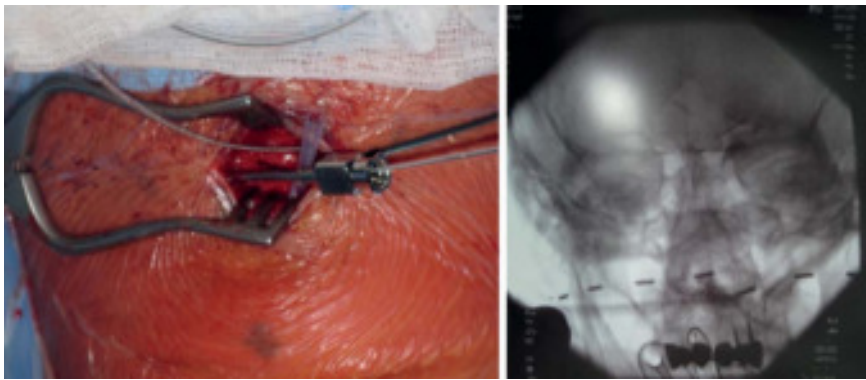


Fig. 2 Placement of the stimulation electrodes.

Furthermore, the electrodes should not be placed too deep, which might lead to unwanted stimulation of the deep short neck muscles or the sternocleidomastoid muscle. In any case, the muscle fascia must not be passed with the Touhy needle, or the course of the greater occipital nerve (GON) will be missed. The position of the electrodes is confirmed via a posteroanterior X-ray, with which they are identified running parallel to the lamina of C1 (◉ Fig 2).

We advise employment of 4-pole electrodes with a large distance between the electrode poles (e.g., Pisces Quad Plus[®], Medtronic Inc., Minneapolis, Minnesota, USA) or an 8-pole electrode (e.g., Octrode[®], ANS St. Jude Medical Inc., St. Paul, Minnesota, USA). The greater interpolar distance grants a large field of stimulation covering the greater occipital nerve. As far as we can tell, there is no advantage in using an 8-pole electrode instead of a 4-pole electrode with a large interpolar distance. We only employ the 8-pole electrode because of its length, since a 4-pole electrode with a sufficient interpolar distance from another company does not exist. From our experience it is not necessary to perform intraoperative test stimulation in order to assure the correct positioning of the leads. The GON runs in a quite constant course around the lamina of the vertebral arch of C1 and passes through the muscle fascia before it ascends to the occiput. If the electrodes are placed parallel to the arch of C1, the stimulation will reach the GON dependably.

Via a transverse, suprascapular incision another subcutaneous pouch for the relief of the strain on the leads was created, before they were directed towards a paramedian incision at the level of Th5. Here, the stimulation electrodes were connected to extension leads, which in turn were connected to an external generator during the test period (◉ Fig. 3). These cables were tunnelled to the left flank, where they were secured to the skin with a non-resorbable suture (e.g., Prolene 2-0[®], Johnson & Johnson GmbH, Neuss, Germany). We covered the exit site with loose cotton draping. Once the patient was back on the ward, we programmed the stimulation parameters.

The polarity of the electrodes should create a large field of stimulation over the occiput. The patient will notice the stimulation as a mild paresthesia extending from the occiput to the parietal region. In the majority of our patients, the largest field of stimulation was achieved by choosing pole 1 of the stimulation electrode (medial pole) as the cathode (regarding the stimulation electrode as a galvanic cell) and pole 3 as the anode. Therefore, the diagram of the electrode reads: “+ / 0 / - / 0”. Placing the anode to pole 4 may lead to unwanted costimulation of the sternocleidomastoid muscle. With the 8-pole electrode, it may be necessary to use both pole 1 and 2 as cathodes and pole 5/6 as the anode (“+ / + / 0 / 0 / - / - / 00”). The impedance of the poles will

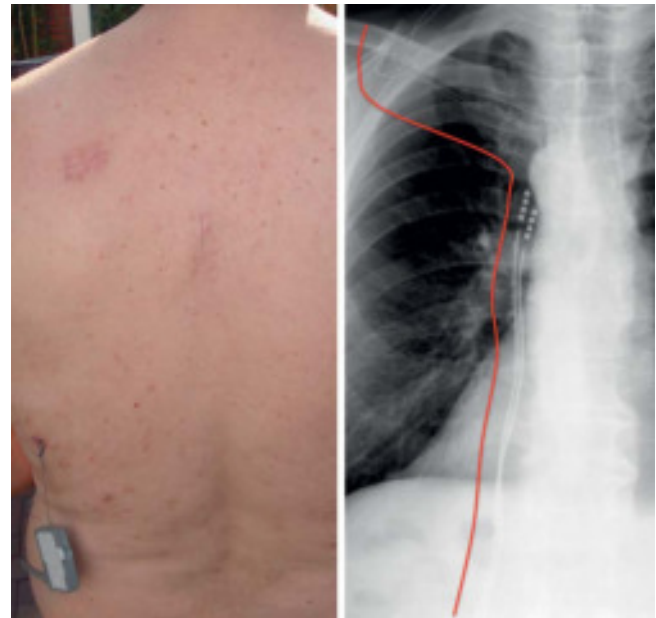

Fig. 3 External stimulation and course of the leads.

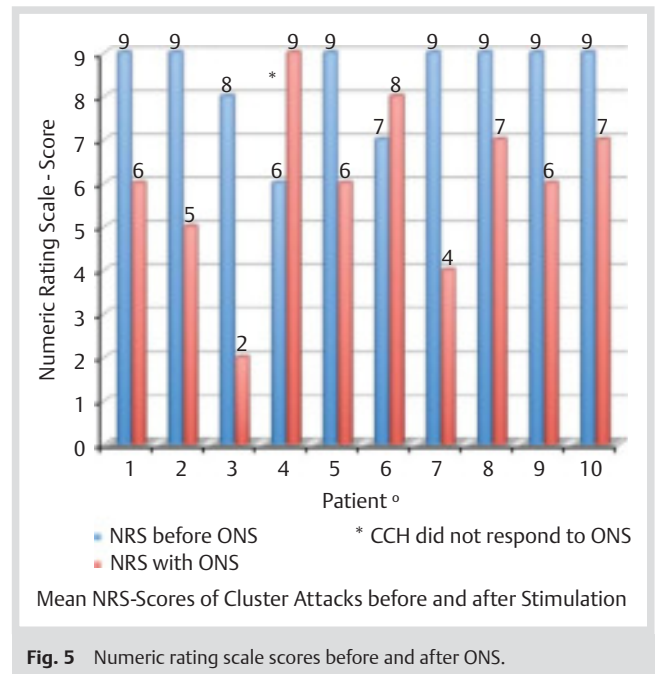
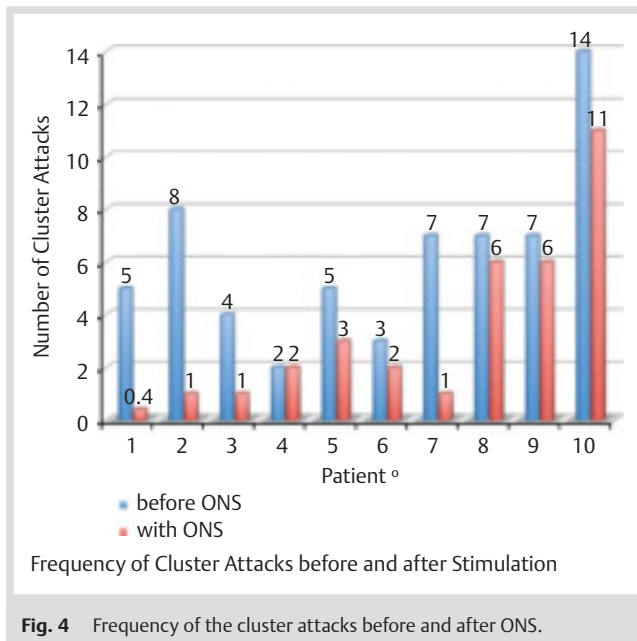
change in the first days after implantation due to resorption of blood and consecutive formation of granulation tissue. Thus, a change of the polarity of the electrode might be required to restore the field of stimulation. In any case, setup of the electrode's poles has to be adjusted to the individual needs of the patient.

In our patients, pulse width and frequency were fixed at 390 μ s and 40 Hz, as a greater pulse width might create a painful sensation. Higher frequencies caused a discomforting stimulation, which patients described as a “constant knocking”. We assume that the higher pulse frequency affected the small deep muscle of the neck (Mm. obliqui and recti). Therefore, we stimulated all patients with the aforementioned parameters.

The patients could freely adjust the stimulation amplitude (current- or voltage-gated dependent on the generator) as they were instructed to apply a voltage that elicited a comfortable paresthesia.

Test period

After implantation of the electrodes, the patients completed their headache diary for another 30 days. Frequency and intensity of the attacks, as well as the use of medication and oxygen during the attacks were recorded. During this period, all patients were seen clinically to check the exit site of the leads for infections and to confirm the correct function of the external genera-



tor. The diaries received interdisciplinary evaluation (OMM, CG, TG, ZK). The SF-36 and pain score were assessed after 30 days. Patients were recommended for implantation of a permanent generator when a decline of the attacks in frequency, intensity, or duration compared to the preoperative baseline was found.

Operation II – implantation of the permanent generator

The patients were free to choose the site for the implantation of the generator, either abdominal or gluteal. The operation was done under general anesthesia with the patient lying on the side (for the abdominal implantation) or in the prone position (if the gluteal implantation was preferred by the patient). After sterile draping, the externalized leads were disconnected from the rest of the externalized cables. A subcutaneous abdominal or gluteal pocket was created right above the muscle fascia, where the generator was fixed by non-resorbable sutures. We confirmed the optimal position of the generator preoperatively by asking the patient to bend forward, backward, and laterally. Contact of the generator to the iliac crest or the lower ribs may cause great discomfort to the patient. The extension leads are guided towards the subcutaneous pocket via a tunnel instrument and are connected to the generator.

Follow-up

The patients were seen clinically after 1 and 3 months, and then afterwards every 3 months. A standardized questionnaire recorded cluster attacks, the pain score and SF-36, use of medication as well as the patient's satisfaction with the operation at every clinical visit. One patient, with whom we kept in regular email contact, went abroad to South America for 10 months.

Results

ONS improved cluster headaches in 9 of 10 patients. One patient had a reduction in intensity of his accompanying tension type headache of 50%, but the cluster attacks were not affected by the stimulation. The stimulation started to be effective, on average,

after 20 days. Almost all patients had severe attacks right after the implantation of the electrodes that lasted for approximately 2 days. The frequency of the attacks declined at first, while the intensity decreased only marginally during the test period. During the follow-up period, the beneficial effect of ONS became even more evident. 9 of 10 patients reported a mean overall improvement of 44% (range 20–90%) of the CCH attacks. The daily frequency of the attacks dropped from a mean of 6 (range 2–14) to 3 (range 0.4–11; ● Fig. 4). Besides the frequency of the attacks, the patients experienced a marked relief in the intensity of the attacks. The NRS moved from a mean of 8 (range 6–9) to 6 (range 2–9; ● Fig. 5).

3 of 10 patients had up to 19 days without cluster attacks. Pain-free days were neither found in the baseline data nor anamnestically in the medical history of the past 6 months before stimulation. 7 patients were able to reduce their consumption rate of acute medication by 69% (range 25–100%). 7 patients were responsive to oxygen during the attack. 4 of them lowered their oxygen consumption by 50% (range 25–75%). 3 patients started a dose decrease in preventive medication.

5 patients underwent a temporal worsening of the cluster attacks during the follow-up period. For several weeks the attacks clustered and compounded in intensity again. These episodes lasted between 3–6 weeks. Naturally, the need for acute medication increased during this period. One patient needed steroid pulse therapy (prednisolone started at 100 mg) to interrupt the episode. Yet, the attacks did not reach the initial frequency or intensity of each individual preoperative baseline. The stimulation parameters were not modified during these cluster episodes.

3 patients required a modification of the polarity of the electrodes due to motion-dependent coinnervation of the deep muscles of the neck or the sternocleidomastoid muscle. By adjusting the polarity, the coinnervation was controlled with a good persisting stimulation field over the occiput.

According to our questionnaires, all patients experienced an improved quality of life. The standardized SF-36 revealed a tendency towards improved sum scales (physical sum scale, emo-

tional well-being), but lacked statistical significance. All patients were content with the operative outcome. 10 out of 10 patients would recommend ONS without restrictions.

Complications

One patient suffered a local infection, leading to explantation of the generator and externalization of the electrodes until the infection healed and before implanting another generator at a different location. On this occasion, presumably, a dislocation of one of the electrodes occurred, which was seen on the postoperative X-ray. However, this dislocation did not affect the stimulation effect. The patient recovered completely and his attacks are well under control (1 attack/day, NRS 2 max). Another patient had to be reoperated because of scar formation around the thoracic connector, which caused discomfort. The patients with abdominal generators experienced a painful pressure on the generator site from time to time, when they lifted or carried heavy objects. This condition was more common with slim individuals. Patients carrying a gluteal generator described a “foreign-body” feeling at the generator site when they sat for a long time on an uncomfortable chair. One patient with a gluteally implanted generator developed a pressure ulcer (2nd degree, superficially located, no superinfection) at the operation site, due to a gain of body weight, that led to a progressively lower waistband. The decubitus was caused by the patient’s belt and successfully treated with dry bandages.

Discussion and Conclusion

Burns et al. were the first to report on successful ONS for CCH patients in a small series of patients [13,15]. They transferred Weiner’s idea of stimulation of the GON for relief of an occipital neuralgia as a mode of action for CCH [14,16–18]. The exact pathophysiological background is unclear so far. Referring to Melzack’s “gate-control theory”, an instant effect of the stimulation can be assumed at the “dorsal root entry zone” (DREZ) [18–20]. Yet, it appears more likely that ONS interferes with several pain-processing circuits. The influence on segmental neuronal networks probably inhibits a nociceptive transmission via the stimulation of afferent A- β -fibers [20–23]. On the second neuron of the trigeminocervical complex, the afferent fibers of the trigeminal nerve and afferences of the upper cervical spinal cord converge. The functional unity of this complex stretches out to C2 and even lower [16,24–27]. The nucleus spinalis of the trigeminal nerve is topographically arranged with the areal innervation of the first trigeminal division situated at the caudal part of the nucleus, which is approximately at the level of C2. The low local resolution of the neuronal networks most likely explains the antinociceptive effect of the ONS, both in the innervation area of the occipital nerve, as well as of the trigeminal nerve [16,25,28,29]. The periaqueductal gray presumably represents a superordinated supraspinal control organ, in this regard, by descending inhibitory control and, thus, modulating the afferent input.

Most of the patients with CCH are deprived of a normal private, social, or working life due to the severe disabling attacks. The frequent onset of the attacks with a consistent need for drugs, the deprivation of sleep during the night, and the inability to proceed with any activities during the attack results in an inability to work. In an online survey, 65% of 200 CCH patients stated

that they had suicidal tendencies at some point during their illness. 9% of the patients committed a parasuicide.

Small series and case reports in the recent literature have shown that bilateral ONS is an effective treatment for refractory CCH [8,15,17,30,31]. In our series, we observed a reduction in attack frequency of 50%, confirming the promising results of the data from the literature. The mean intensity of a single attack measured by the NRS declined from 8 to 6. 2 of 3 were operated at the same time. Considering that 3 of the patients have only been followed for 3 and 5 months, respectively, we expect further improvement, especially for these patients. The need for acute medication during the attacks declined by 69%, and 4 of the patients responsive to oxygen reduced their oxygen consumption by 50%. All patients reported an improvement in quality of life, although we were not able to find a statistical significance in the SF-36. The latter might be due to the fact that the SF-36 is not an ideal tool for the measurement of life quality in patients with CCH, as headaches differ in the patients’ perception from other symptomatic pain syndromes.

3 of our patients reported pain-free periods, up to 19 days during the follow-up, a condition that the patients had not experienced for a long time. Neither in the baseline data nor in the 6-month period prior to stimulation any of our patients had a single pain-free interval. On the other hand, 5 of our patients had an episodic relapse of their CCH for several weeks despite stimulation. Even though the cluster attacks did not reappear with the same intensity compared to before beginning ONS, our patients needed more medication and oxygen during the attacks and the NRS of the attacks increased over this time. It is known that episodic changes occur in CCH, yet we doubt that these episodic fluctuations mask the positive effect of the ONS. Our patients have suffered from CCH for a mean of 6 years and are familiar with the undulatory phases of the CCH. Therefore, a coincidental improvement of the underlying disease by a naturally occurring episode does not seem plausible.

The complications that were seen in the patients underline the fact that ONS has some risks, making it even more necessary to select the patients for stimulation very carefully. Yet, compared to the side effects and complications of other neuromodulative procedures, from our experience, ONS is still the surgical treatment with the lowest risks for the patient [11,32–35]. However, prospective double-blinded clinical trials are still lacking. It has to be kept in mind that the collective of patients, after exhausting all conservative resources, will be small in all circumstances. A sham procedure to rule out a “placebo” effect will not be possible for 2 reasons: 1) the implantation of the electrodes will have a local effect no matter whether they are activated or not, and 2) patients, from what we know today, should feel a mild paraesthesia on the occiput during stimulation. For the future, a change of the stimulation intensity to subthreshold stimulation might bring new insights, while optimal stimulation parameters remain unclear. Prospective studies will have to investigate whether subthreshold stimulation is appropriate to affect refractory CCH.

A prospective observational clinical trial is currently being conducted at our clinic to investigate the ideal stimulation parameters of ONS for the treatment of CCH and we have been recruiting patients since October 2009.

Conclusion



We showed with our data that ONS is an effective treatment for patients with CCH. However, one should be aware that long-term results are still lacking and that ONS potentially has adverse events. Nevertheless, patients with CCH should be recommended for ONS when CH is refractory to medication therapy.

Conflict of Interest: None

References

- Katsarava Z, Obermann M, Yoon MS et al. Prevalence of cluster headache in a population-based sample in Germany. *Cephalalgia* 2007; 27: 1014–1019
- May A. Cluster headache: pathogenesis, diagnosis, and management. *Lancet* 2005; 366: 843–855
- The International Classification of Headache Disorders. 2nd edition. *Cephalalgia* 2004; 24 (Suppl. 1): 9–160
- Treatment of acute cluster headache with sumatriptan. The Sumatriptan Cluster Headache Study Group. *N Engl J Med* 1991; 325: 322–326
- May A, Leone M, Afra J et al. EFNS guidelines on the treatment of cluster headache and other trigeminal-autonomic cephalalgias. *Eur J Neurol* 2006; 13: 1066–1077
- Hedlund C, Rapoport AM, Dodick DW et al. Zolmitriptan nasal spray in the acute treatment of cluster headache: a meta-analysis of two studies. *Headache* 2009; 49: 1315–1323
- May A, Evers S, Straube A et al. Treatment and prophylaxis for cluster headaches and other trigeminal autonomic headaches. Revised recommendations of the German Migraine and Headache Society. *Schmerz* 2005; 19: 225–241
- Goadsby PJ, Cittadini E, Burns B et al. Trigeminal autonomic cephalalgias: diagnostic and therapeutic developments. *Curr Opin Neurol* 2008; 21: 323–330
- Diener HC, Göbel H, Pfaffenrath V et al. Therapy of cluster headaches. *Dtsch Arzteztg* 1998; 95 (44): 2760–2769
- Franzini A, Ferroli P, Leone M et al. Stimulation of the posterior hypothalamus for treatment of chronic intractable cluster headaches: first reported series. *Neurosurgery* 2003; 52: 1095–1099; discussion 1099–1101
- Leone M, Proietti Cecchini A, Franzini A et al. Lessons from 8 years' experience of hypothalamic stimulation in cluster headache. *Cephalalgia* 2008; 28: 787–797; discussion 798
- Starr PA, Barbaro NM, Raskin NH et al. Chronic stimulation of the posterior hypothalamic region for cluster headache: technique and 1-year results in four patients. *J Neurosurg* 2007; 106: 999–1005
- Burns B, Watkins L, Goadsby PJ. Treatment of medically intractable cluster headache by occipital nerve stimulation: long-term follow-up of eight patients. *Lancet* 2007; 369: 1099–1106
- Weiner RL, Reed KL. Peripheral neuromodulation for control of intractable occipital neuralgia. *Neuromodulation* 1999; 2: 217–221
- Burns B, Watkins L, Goadsby PJ. Treatment of intractable chronic cluster headache by occipital nerve stimulation in 14 patients. *Neurology* 2009; 72: 341–345
- Goadsby PJ. Neuromodulatory approaches to the treatment of trigeminal autonomic cephalalgias. *Acta Neurochir Suppl* 2007; 97: 99–110
- Goadsby PJ, Bartsch T, Dodick DW. Occipital nerve stimulation for headache: mechanisms and efficacy. *Headache* 2008; 48: 313–318
- Goadsby PJ, Cohen AS, Matharu MS. Trigeminal autonomic cephalalgias: diagnosis and treatment. *Curr Neurol Neurosci Rep* 2007; 7: 117–125
- Goadsby PJ, Cohen AS. Pathophysiology and treatment of trigeminal autonomic cephalalgias. *Schmerz* 2008; 22 (Suppl. 1): 7–10
- Melzack R, Wall PD. Pain mechanisms: a new theory. *Science* 1965; 150: 971–979
- Chung JM, Lee KH, Hori Y et al. Factors influencing peripheral nerve stimulation produced inhibition of primate spinothalamic tract cells. *Pain* 1984; 19: 277–293
- DeLeo JA. Basic science of pain. *J Bone Joint Surg Am* 2006; 88 (Suppl. 2): 58–62
- Stojanovic MP, Abdi S. Spinal cord stimulation. *Pain Physician* 2002; 5: 156–166
- Bartsch T, Goadsby PJ. The trigeminocervical complex and migraine: current concepts and synthesis. *Curr Pain Headache Rep* 2003; 7: 371–376
- Bartsch T, Paemeleire K, Goadsby PJ. Neurostimulation approaches to primary headache disorders. *Curr Opin Neurol* 2009; 22: 262–268
- Busch V, Frese A, Bartsch T. [The trigemino-cervical complex. Integration of peripheral and central pain mechanisms in primary headache syndromes]. *Schmerz* 2004; 18: 404–410
- Garrison DW, Foreman RD. Decreased activity of spontaneous and noxiously evoked dorsal horn cells during transcutaneous electrical nerve stimulation (TENS). *Pain* 1994; 58: 309–315
- Goadsby PJ. Neurostimulation in primary headache syndromes. *Expert Rev Neurother* 2007; 7: 1785–1789
- Bartsch T, Goadsby PJ. Increased responses in trigeminocervical nociceptive neurons to cervical input after stimulation of the dura mater. *Brain* 2003; 126: 1801–1813
- Jasper JF, Hayek SM. Implanted occipital nerve stimulators. *Pain Physician* 2008; 11: 187–200
- Schwedt TJ. Occipital nerve stimulation for medically intractable headache. *Curr Pain Headache Rep* 2008; 12: 62–66
- Leroux E, Ducros A. Cluster headache. *Orphanet J Rare Dis* 2008; 3: 20
- Schoenen J, Di Clemente L, Vandenhede M et al. Hypothalamic stimulation in chronic cluster headache: a pilot study of efficacy and mode of action. *Brain* 2005; 128: 940–947
- Meyer SC, Swartz K, Johnson JP. Quadriparesis and spinal cord stimulation: case report. *Spine* 2007; 32: E565–E568
- Spincemaille GH, Klomp HM, Steyerberg EW et al. Technical data and complications of spinal cord stimulation: data from a randomized trial on critical limb ischemia. *Stereotact Funct Neurosurg* 2000; 74: 63–72