

Novel Use of Narrow Paddle Electrodes for Occipital Nerve Stimulation—Technical Note

Kumar Abhinav, MRCS, Nicholas D. Park, FRCS (SN),
Savithru K. Prakash, MRCS, Sarah Love-Jones, FRCA,
Nikunj K. Patel, FRCS (SN)

Objectives: Occipital nerve stimulation (ONS), an established treatment for medically intractable headache syndromes, has lead migration rates quoted up to 24%. In a series of patients with ideal characteristics for this treatment modality, we describe an operative technique for ONS involving the novel use of narrow paddle electrodes: “S8 Lamitrode” (St. Jude Medical [SJM], St. Paul, MN, USA).

Materials and Methods: Five patients (occipital neuralgia [ON] = 4; chronic migraine [CM] = 1) were treated with ONS between 2010 and 2011. All patients had a successful trial of peripheral neurostimulation (Algotec Ltd, Crawley, UK) therapy. Operative technique involved the use of a park-bench position, allowing simultaneous exposure of the occipital and infraclavicular regions. Through a retromastoid/occipital incision just beneath the external occipital protuberance, exposing the extr fascial plane, the S8 Lamitrode is implanted to intersect both greater occipital nerves for bilateral pain or unilateral greater and lesser occipital nerves for unilateral ON or with significant component of the pain relating to the lesser occipital nerve.

Results: Over the median follow-up of 12 months, there were no episodes of lead migration or revision. There also was significant improvement in symptoms in all patients.

Conclusions: This is the first reported use of S8 Lamitrode electrode for ONS. This narrow electrode is suited for this role leading to minimal trauma during surgical placement, facilitates resolution of problems with lead migration, and optimizes effect with stimulation focused more in direction of the occipital nerves without skin involvement. To date, the SJM Genesis neurostimulation system, with percutaneous electrodes only, is CE mark approved in Europe for peripheral nerve stimulation of the occipital nerves for the management of pain and disability for patients diagnosed with intractable CM. Further developments and studies are required for better devices to suit ONS, thereby avoiding frequently encountered problems and which may clarify the role of paddle leads in ONS.

Keywords: Lead migration, occipital nerve stimulation, occipital neuralgia

Conflict of Interest: The authors reported no conflict of interest.

INTRODUCTION

Occipital nerve stimulation (ONS) refers to the stimulation of the distal branches of C2-3 (greater and lesser occipital nerves) and has been used to treat medically intractable headache syndromes including migraine, occipital neuralgia (ON), and cluster headache (1–6). The indications for implantation of permanent occipital neurostimulators are likely to continue expanding. The surgical technique employed for implantation of ONS has been previously described (5,7). The two commonly employed surgical approaches for permanent ONS implantation include either a 2-cm midline incision at the C1 level with subsequent insertion of lead with a lateral trajectory from that point (2,4) or a lateral approach involving an incision medial and inferior to mastoid process at the C1 level (3,6). Percutaneous or paddle leads are employed in either of these approaches.

Complications associated with ONS include lead migration, a frequently encountered serious problem (2,7,8) with rates quoted up to 24% (1). We describe a case series of five patients with ideal characteristics for this treatment modality involving the novel (off-label) use of S8 Lamitrode (St. Jude Medical [SJM], St. Paul, MN, USA) for ONS,

subsequently minimizing lead migration. This is probably the first report of this electrode used for an application other than spinal cord stimulation.

MATERIALS AND METHODS

The S8 Lamitrode is a narrow surgical (S8) contact paddle lead, which was developed for minimally invasive and percutaneous

Address correspondence to: Nikunj K. Patel, FRCS (SN), Department of Neurosurgery, Institute of Clinical Neurosciences, Frenchay Hospital, Frenchay Park Road, Bristol BS16 1LE, UK. Email: nik.patel@nbt.nhs.uk

Department of Neurosurgery, Institute of Clinical Neurosciences, Frenchay Hospital, Bristol, UK

For more information on author guidelines, an explanation of our peer review process, and conflict of interest informed consent policies, please go to <http://www.wiley.com/bw/submit.asp?ref=1094-7159&site=1>

Source(s) of financial support: None.

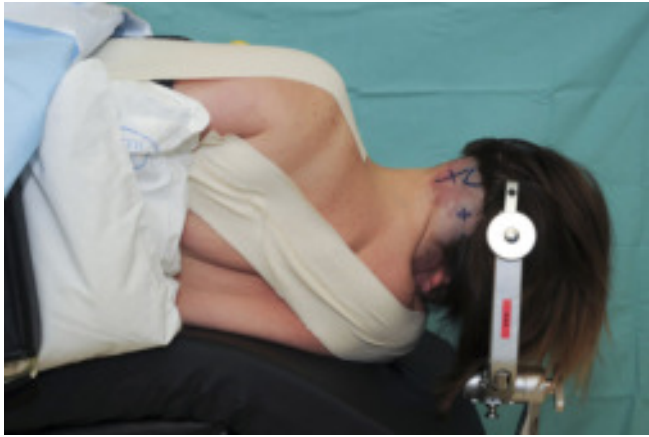

Figure 1. Park-bench position with simultaneous exposure of the occipital and infraclavicular regions.

spinal epidural implantation, using initially a 10-gauge Tuohy needle and now an "Epiducer" system, for spinal cord stimulation. The lead is shielded on one side and with the contacts facing the other side the stimulation is focused only in one direction rather than circumferentially as with a percutaneous lead.

Five patients (ON = 4; chronic migraine [CM] = 1) were treated with ONS between 2010 and 2011. Three patients were treated for unilateral ON with one treated for bilateral ON. All patients had a successful trial of peripheral neurostimulation (PENS) therapy prior to the operative procedure. PENS is a mobile transient stimulating system that potentially obviates the need to implant trial lead and in our experience has been found to be of value in predicting the eventual response to ONS.

Operative Technique

The park-bench position was used to allow simultaneous exposure of the occipital and infraclavicular regions (Fig. 1). For bilateral pain, a vertical incision is made in the retromastoid/occipital region approximately 4–5 cm from the midline, at a level just beneath the external occipital protuberance (EOP). The occipital fascia is identified and a plane external to it is created with dissection continued toward the midline. Beyond this, a Tuohy needle is inserted, and utilizing the Seldinger technique and Epiducer, the S8 Lamitrode is implanted. This ensures placement across both greater occipital nerves, with correct electrode orientation, and distally surrounding tissue tightly holds Lamitrode in place. The S8 Lamitrode is then secured to the fascia (Fig. 2), followed by tunneling of the lead to the infraclavicular region for connection to the "Eon Mini" implantable pulse generator (SJM).

For unilateral ON pain, the procedure is modified with the use of a midline or retromastoid vertical incision at a level just beneath the EOP, depending on whether capture of greater or lesser occipital nerves is warranted, with implantation in the extrafascial plane. The lead is then tunneled to the exposed infraclavicular pocket. Surgical time of implantation is usually less than an hour. Postoperatively skull x-rays (Figs. 3 and 4) are obtained in order to check final lead position, which also acts as baseline film for potential comparison in the future in suspected cases of lead migration or fracture.

RESULTS

Median follow-up was 12 months (6–18 months). Median visual analog scale preoperatively and postoperatively was nine and

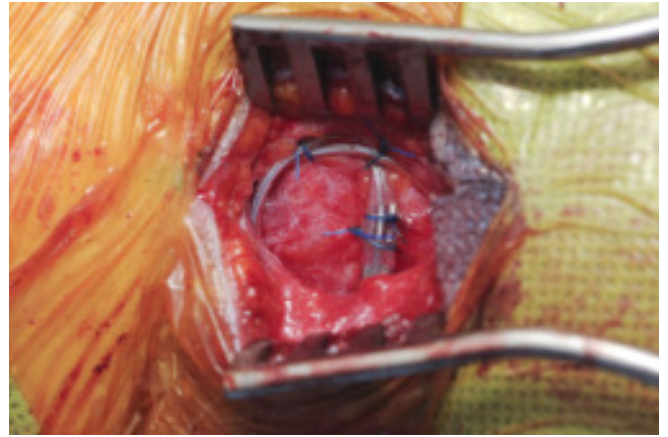


Figure 2. S8 Lamitrode secured to the fascia.

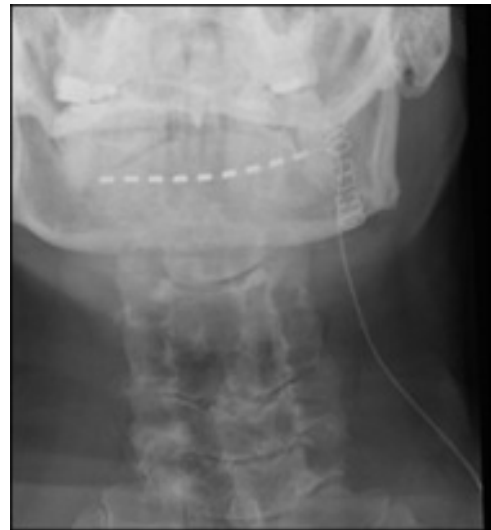

Figure 3. Occipital nerve stimulation for bilateral occipital neuralgia.

zero, respectively, for patients with ON. Patient with CM had 80% reduction in frequency of attacks from five to one per month. Over the follow-up period, there were no episodes of lead migration or revision.

DISCUSSION AND CONCLUSION

Lead migration requiring surgical revision has been reported previously with spinal cord stimulators (9,10). Lead migration with ONS usually clinically results in patients experiencing a change in stimulation pattern, cervical pain, or reduction or loss of control of headache (11). The mechanism underlying migration may include movement-related stress on the components in the very mobile cervical region, which is not seen with SCS. Various strategies have been reported toward reducing lead migration. Patients have been prescribed soft collars for ten days postimplantation and further advised to minimize head movement, bending, and twisting for six weeks postimplantation to allow time for "scarring" and subsequent stability (5,7). Paddle style leads are thought to be less likely to migrate because of its larger size and the relative ease with which it

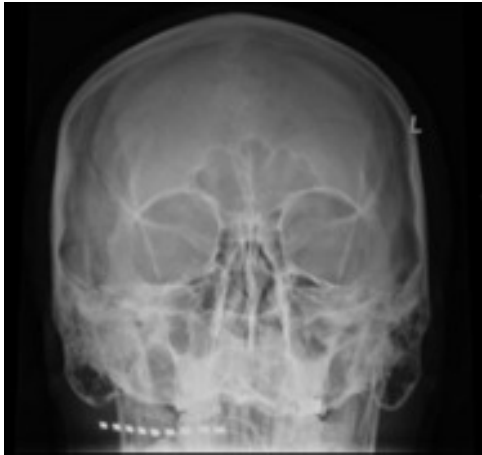


Figure 4. Occipital nerve stimulation for unilateral occipital neuralgia.

can be secured to the fascia (11,12); however, in comparison to the percutaneous lead, these leads do require increased dissection and also have been reported to migrate (3). Additional techniques employed to minimize migration have included the use of silicone glues in conjunction with silicone anchors (5). In this technique, in addition to the glue, nylon sutures are applied around the anchor. A single suture secures the lead and anchor together after the glue is applied followed by two or more sutures to secure lead/anchor unit to the tissue (5). A further technique describing implantation of ONS via a retromastoid to infraclavicular approach, with advantages in patient positioning, ease of surgical approach, and minimization of mechanical stress on components, also has been reported (13).

This is the first reported use of S8 Lamitrode electrode for ONS. The S8 Lamitrode, a narrow paddle electrode, is suited for this role with its ease and minimal trauma with implantation. It can be secured to the fascia, thereby reducing the risk of lead migration. Furthermore, the unidirectional orientation of electrical contacts maximizes neurostimulation of the occipital nerves while minimizing any collateral skin stimulation, although implantation in the extrafascial plane that overlies the nerves is mandatory. Apart from maximizing neurostimulation, this also allows the lead to be secured to the fascia for stability.

To date, the SJM Genesis neurostimulation system, with percutaneous electrodes only, is CE mark approved in Europe for peripheral nerve stimulation of the occipital nerves for the management of pain and disability for patients diagnosed with intractable CM.

Further developments and studies are required for better devices to suit ONS, thereby avoiding frequently encountered problems and which may clarify the role of paddle leads in ONS.

Authorship Statements

All authors contributed significantly to the project including preparation and review of the manuscript.

How to Cite this Article:

Abhinav K., Park N.D., Prakash S.K., Love-Jones S., Patel N.K. 2013. Novel Use of Narrow Paddle Electrodes for Occipital Nerve Stimulation—Technical Note. *Neuromodulation* 2013; 16: 607–609

REFERENCES

1. Saper JR, Dodick DW, Silberstein SD et al. Occipital nerve stimulation for the treatment of intractable chronic migraine headache: ONSTIM feasibility study. *Cephalalgia* 2011;31:271–285.
2. Schwedt TJ, Dodick DW, Hentz J, Trentman TL, Zimmerman RS. Occipital nerve stimulation for chronic headache—long-term safety and efficacy. *Cephalalgia* 2007;27:153–157.
3. Magis D, Allena M, Bolla M, De Pasqua V, Remacle JM, Schoenen J. Occipital nerve stimulation for drug-resistant chronic cluster headache: a prospective pilot study. *Lancet Neurol* 2007;6:314–321.
4. Burns B, Watkins L, Goadsby PJ. Treatment of medically intractable cluster headache by occipital nerve stimulation: long-term follow-up of eight patients. *Lancet* 2007;369:1099–1106.
5. Rogers LL, Swidan S. Stimulation of the occipital nerve for the treatment of migraine: current state and future prospects. *Acta Neurochir Suppl* 2007;97:121–128.
6. Weiner RL, Reed KL. Peripheral neurostimulation for control of intractable occipital neuralgia. *Neuromodulation* 1999;2:217–221.
7. Trentman TL, Zimmerman RS. Occipital nerve stimulation: technical and surgical aspects of implantation. *Headache* 2008;48:319–327.
8. Popeney CA, Aló KM. Peripheral neurostimulation for the treatment of chronic, disabling transformed migraine. *Headache* 2003;43:369–375.
9. Spincemaille GH, Klomp HM, Steyerberg EW, van Urk H, Habbema JD, ESES Study Group. Technical data and complications of spinal cord stimulation: data from a randomized trial on critical limb ischemia. *Stereotact Funct Neurosurg* 2000;74:63–72.
10. North RB, Kidd DH, Zahurak M, James CS, Long DM. Spinal cord stimulation for chronic, intractable pain: experience over two decades. *Neurosurgery* 1993;32:384–394.
11. Oh MY, Ortega J, Bellotte JB, Whiting DM, Aló K. Peripheral nerve stimulation for the treatment of occipital neuralgia and transformed migraine using a c1-2-3 subcutaneous paddle style electrode: a technical report. *Neuromodulation* 2004;7:103–112.
12. Kapural L, Sable J. Peripheral nerve stimulation for occipital neuralgia: surgical leads. *Prog Neurol Surg* 2011;24:86–95.
13. Trentman TL, Slavin KV, Freeman JA, Zimmerman RS. Occipital nerve stimulator placement via a retromastoid to infraclavicular approach: a technical report. *Stereotact Funct Neurosurg* 2010;88:121–125.