

22. Fusco M, D'Andrea G, Miccichè F, Stecca A, Bernardini D, Cananzi AL. Neurogenic inflammation in primary headaches. *Neurol Sci.* 2003;24(Suppl. 2):S61-S64.
23. Shibagaki Y, Fujita T. Thrombotic microangiopathy in malignant hypertension and hemolytic uremic syndrome (HUS)/thrombotic thrombocytopenic purpura (TTP): Can we differentiate one from the other? *Hypertens Res.* 2005;28:89-95.
24. Vanmolkot FH, Van Bortel LM, de Hoon JN. Altered arterial function in migraine of recent onset. *Neurology.* 2007;68:1563-1570.

---

## Implanted Auriculotemporal Nerve Stimulator for the Treatment of Refractory Chronic Migraine

Thomas Simopoulos, MD; Zahid Bajwa, MD; George Lantz, DO; Steve Lee, MD; Rami Burstein, PhD

**Objective.**—To report a case of improved pain control and function in a patient with chronic migraine after treatment with auriculotemporal nerve stimulation.

**Methods.**—The patient is a 52-year-old woman with refractory pain in the bilateral temporal distribution and marked phonophobia as a result of chronic migraine.

**Results.**—After a successful trial period, the patient underwent implantation of bilateral peripheral nerve stimulators targeting the auriculotemporal nerves. At 16 months of follow up, her average pain intensity declined from 8-9/10 on the numeric rating scale to 5/10. Her function improved as assessed by the Migraine Disability Assessment, from total disability (grade IV) to mild disability (grade II). Her phonophobia became far less debilitating.

**Conclusion.**—Auriculotemporal nerve stimulation may be useful tool in the treatment of refractory pain in the temporal distribution due to chronic migraine.

**Key words:** headache, trigeminal, pain, nociceptor, CGRP, calcitonin gene-related protein

---

Chronic daily headache (CDH) afflicts 4-5% of the population and represents a significant public health and economic burden.<sup>1</sup> CDH is defined as headache of at least 4 hours duration, with a frequency of 15 days or more per month for more than 3 months.<sup>2</sup> A gradual transformation of migraine from paroxysmal headache in childhood to daily headache during the most productive years of adulthood is a leading cause of disabling CDH.<sup>3</sup> In fact, 94% of patients with CDH experience additional severe paroxysmal exacerbations. Chronic migraines (CM) are the root of incapacitating CDH and are often associated with abortive

medication overuse as well as neuropsychiatric morbidities such as depression and anxiety.<sup>4</sup>

Current strategies for CM treatment include hospitalization, disruption of abortive medications with the use of corticosteroids, ergot alkaloids such as dihydroergotamine, and enhancement of prophylactic agents such as amitriptyline.<sup>5</sup> To date, only topiramate and botulinum toxin type A have shown efficacy for CM in several randomized controlled trials.<sup>6,7</sup> Outpatient management may further involve behavioral modification and biofeedback therapies. Nevertheless, success rates are generally low and relapses are common.<sup>8</sup> For these reasons, patients often resort to opioid therapy, which is beneficial in about 25% of all refractory CDH patients.<sup>9</sup> The implementation of opioids in refractory migraine may reduce the response to nonsteroidal anti-inflammatory drugs.<sup>10</sup>

---

**From the Beth Israel Deaconess Medical Center – Anesthesia, Boston, MA, USA.**

**Address all correspondence to S.C. Lee, BIDMC – Anesthesia, 770 Brookline Avenue, Boston, MA 02215, USA.**

Accepted for publication April 2, 2010.

---

*Conflict of Interest:* None

A recently introduced treatment option for chronic refractory headache involves the use of subcutaneous implanted neurostimulator leads. Non-painful stimulation of peripheral nerves has been well known to render analgesia. In 1999, Weiner and Reed applied this concept of nerve stimulation for medically intractable headache to the peripheral afferents of C1-C3.<sup>11</sup> Since then many investigators have reported success using occipital nerve stimulation (ONS) in CM, chronic cluster headache and hemicrania continua.<sup>12</sup> However, temporal distributions of pain are common in CM, and occipital stimulation does not reliably provide paresthesias in trigeminal nerve distributions.<sup>13</sup> Here we describe peripheral neurostimulation of bilateral auriculotemporal nerves that rendered significant reduction in base-line pain intensity and frequency of CM exacerbations confined to the bitemporal regions.

## CASE REPORT

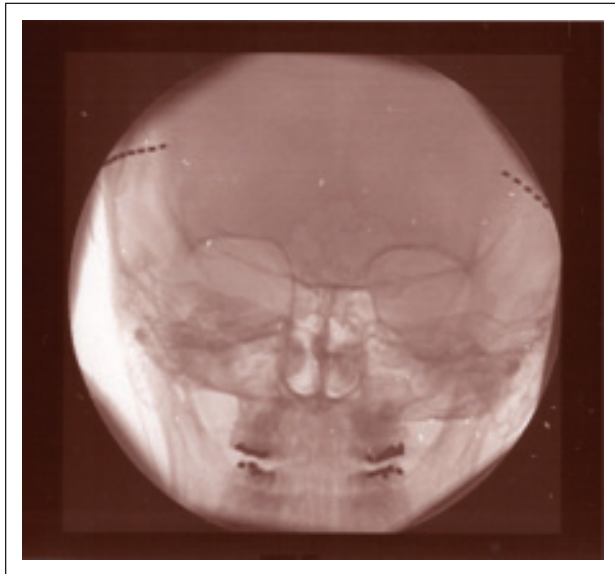
The patient is a 52-year-old woman with history of migraine headaches since childhood and who presented for treatment of her CM in 2005. Her past medical history was significant only for sinus surgery and depression that was well managed on fluoxetine. She suffered daily bitemporal headache at an intensity of 8-9/10 on a numeric rating scale. She perceived her headache as a vise-like tension or pressure on the outside of her calvaria and she testified to extreme phonophobia. She worked part time as an instructional learning assistant because she could not endure her former job as a full-time schoolteacher. She used earplugs daily because usual school noises (eg, whistles, fire alarm, and shouting) triggered severe migraines. The patient became totally disabled, and even withdrew from most social and leisure activities.

Over the years, the patient had received numerous abortive medications with declining success that included: acetaminophen with codeine, multiple triptans (almotriptan, frovatriptan, eletriptan), acetaminophen/butalbital/caffeine, multiple nonsteroidal anti-inflammatory drugs, atenolol, amitriptyline, prednisone, caffeine/ergotamine, and metaxalone. She had tried multiple prophylactic agents with declining benefit that included valproate, topiramate, verapamil, doxepin, gabapentin, amitrip-

tyline, and atenolol. Finally a trial of oxycodone (sustained and immediate release) was without success.

Magnetic resonance imaging of the brain and arteries was negative. The cervical spine was significant only for arthrosis of the C5/6 and C6/7 facet joints. Interventional procedures included bilateral C2 dorsal root ganglion steroid, cervical epidural steroid injections, trigger point injections, greater occipital nerve blocks, medial branch blocks of C5/6 and C6/7 facets and third occipital nerve cervical blocks, all of which failed to offer relief. Infusion therapies with IV lidocaine as well as auriculo-temporal nerve blocks followed by botulinum toxin-A injections did not alleviate the patient's condition even transiently.

By early 2008, the patient was completely incapacitated by her CM. Her functional status as evaluated by the Migraine Disability Assessment (MIDAS) Questionnaire was 225, indicating severe disability (Grade IV). Given the patient's lack of response to numerous treatments, absence of analgesic abuse, and favorable psychological profile, we felt she was a candidate for peripheral nerve stimulation. In May 2008, the patient underwent a temporary 3-week trial of a percutaneously placed peripheral nerve stimulator trial targeting the auriculo-temporal nerves bilaterally. During the trial the patient reported at least a 50% reduction in headache intensity and improvement in daily function. A permanent bilateral auriculo-temporal nerve stimulator system using two 8 contact leads was implanted the subsequent month (Figs. 1 and 2). This did not require approval from the institutional review board. The leads were tunneled to the base of the neck and connected to a rechargeable pulse generator system (EON™, St. Jude Medical Neuromodulation Division, Plano, TX, USA). We report here the result of a 16-month period of bilateral auriculo-temporal nerve stimulation. During this period, the MIDAS scores ranged from 6-10 (Grade II) with an average pain intensity of 5/10 on the numeric rating scale. She was able to attend musical concerts, an activity she had avoided for years. She also reported isolated bouts of intense headaches that last about 6 days at an intensity of 8-9/10. She continues on topiramate

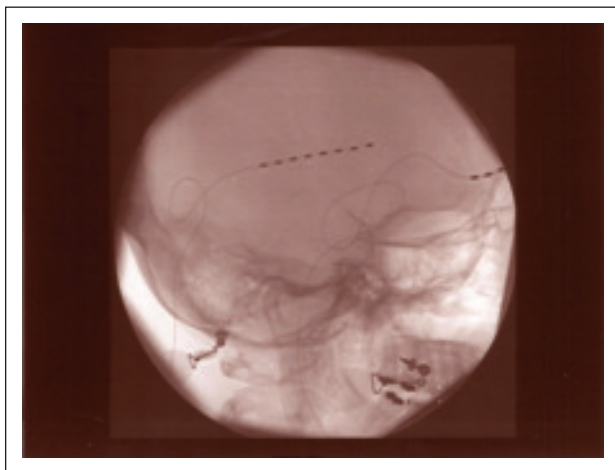


**Fig 1.—Patient image (AP view) after octrode placement over sutures.**

600 mg/day and uses tramadol 50 mg tablets (4-5 days) when she has exacerbations.

## DISCUSSION

Migraine headaches beginning in childhood as in the case of our patient can be progressive and evolve into severe CDH that can have deleterious effects on function during the most productive years.<sup>3</sup> Gradual development of CDH from paroxysmal headache over a time period of a decade is the most common



**Fig 2.—Patient image (lateral view) after octrode placement over sutures.**

clinical course.<sup>5</sup> Patients often report declining benefit from abortive and prophylactic medication treatments. While elimination of abortive medication overuse has in general a high success rate in improving CDH, it may account for only as little as 31% in CM. CM is now believed to be a form of primary neurovascular headache that is likely to result from brain dysfunction.<sup>14</sup>

Over the past decade, ONS has been reported to relieve the pain and improve function in CDH as a result of migraine. In a prospective case series of 25 patients with CM followed on average 18.3 months, Popeney and Alo reported that all patients had a 50% decrease in pain intensity using ONS.<sup>15</sup> All patients had severe disability (grade 4) as assessed by MIDAS prior to implantation of an ONS. On follow up after implantation of an ONS, 75% achieved mild or no disability. Oh et al reported similar high success rates in 10 patients with CM treated with ONS that were followed for 6 months.<sup>16</sup> Finally, Martharu et al retrospectively reported 8 patients with CM who were followed between 1 and 4 years with excellent pain relief.<sup>17</sup>

However, in our experience, regional head pain from CM in distributions other than the occiput is not reliably relieved by ONS. This observation holds true despite the convergence of cervical afferents and trigeminal afferents in the trigeminocervical complex. Paresthesia induced by ONS is primarily confined to the posterior scalp as reported by Trentman et al.<sup>13</sup> We therefore chose to stimulate the distribution of the auriculotemporal nerve that corresponds to the distribution of the patient's chronic pain complaints. Recent animal data suggest that pain of intracranial origin can spread to extracranial structures through meningeal pain fibers that cross the calvaria by following the different suture lines (Fig. 3).<sup>18</sup> The temporal bone that corresponds to a common site of headache in CM has sutures with parietal, sphenoid, occipital, and zygomatic bones that may carry many nociceptive fibers. If this anatomy holds true in humans, it is not unreasonable to propose that ONS is in a position to modulate the activity of meningeal nociceptors that traverse the sutures. It may also explain why ONS works in complete occipital nerve transection.<sup>19</sup> It is very well known that non-painful

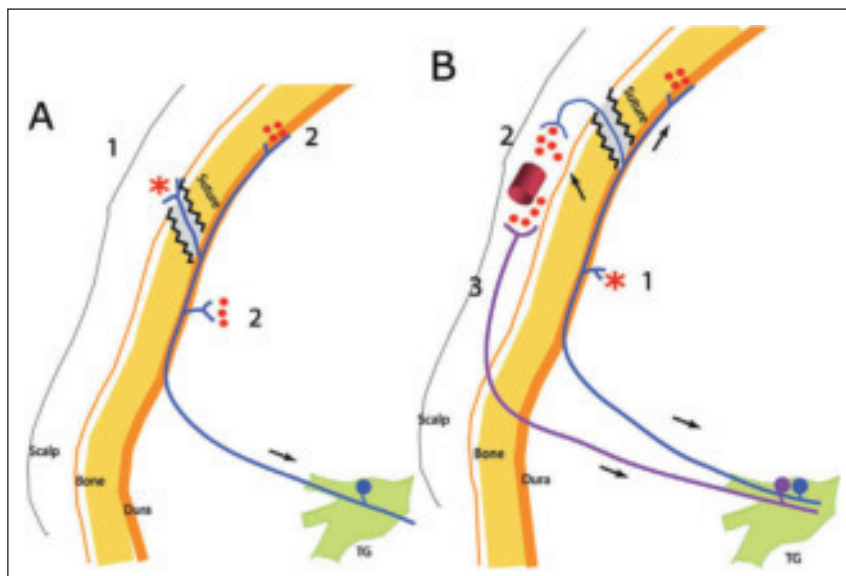


Fig 3.—(A) Extracranial origin of intracranial pain – action potentials generated at extracranial collaterals of meningeal pain fibers (1) spread antidromically to collaterals that terminate inside the cranium (2). Result: local release of proinflammatory neuropeptides and activation of neighboring meningeal nociceptors (2). (B) Intracranial origin of extracranial pain – action potentials generated at intracranial meningeal pain fibers (1) spread antidromically to collaterals that terminate outside the cranium (2). Result: local release of proinflammatory neuropeptides in the scalp and activation of neighboring somatic nociceptors (3). \*Original site of activation. Red dots represent local release of inflammatory neuropeptides (eg, calcitonin gene-related protein [CGRP], substance P).

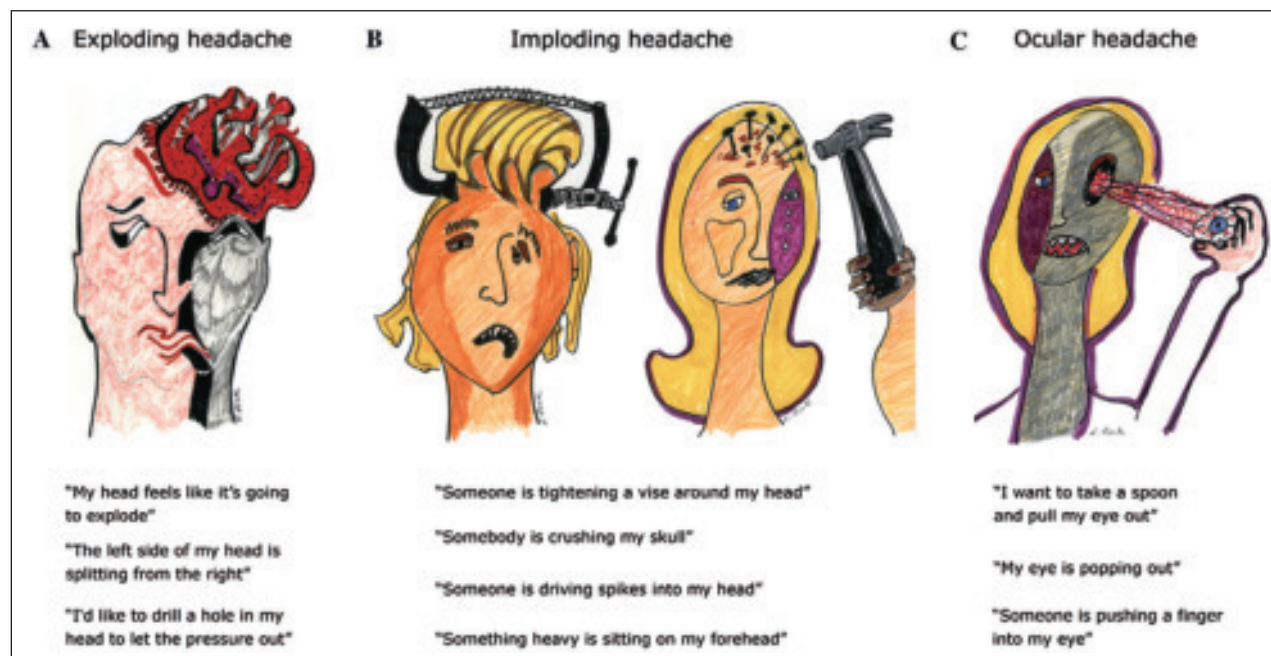


Fig 4.—Patient descriptors of (A) exploding headache, (B) imploding headache, and (C) ocular headache.



stimulation of peripheral nerves can exert analgesic effects and have been used for multiple intractable neuropathic pain states.<sup>20,21</sup> The mechanisms of analgesic benefit are likely to be multiple sites in the nervous system, but so far little is known on the exact mode of action(s). The most often cited mechanism is the “gate-control theory,” whereby the activation of large myelinated A-beta fibers leads to inhibition of small diameter nociceptive fibers.<sup>22,23</sup>

Interestingly, our patient derived marked improvement in phonophobia that affects up to 73% of patients with CM.<sup>24</sup> She also derived sustained improvement in function as evaluated by MIDAS. Aside from our patient having failed multiple modalities, absence of medication overuse, and a favorable psychological profile, there is no specific guide(s) for patient selection when considering peripheral nerve stimulation in CM. Nerve blocks when used as a screening criterion for ONS have failed to consistently predict outcome, as did auriculotemporal nerve blocks for our patient.<sup>12</sup> Interestingly, the use of botulinum toxin A in migraine prophylaxis was reported to be more efficacious in patients with headaches perceived predominantly as crushing or clamped (imploding headache) than those who experience pressure buildup inside the head only (exploding headache) (Fig. 4).<sup>25</sup> Patients with migraines described as imploding type, as in the case of our patient, are thought to have a significant extracranial sensory component that may be more amenable to neuromodulation. Clearly, more studies are necessary to delineate the CM population that is more likely to respond to peripheral nerve stimulation in order to guide treating physicians and design future randomized controlled trials.

## CONCLUSION

Peripheral nerve stimulation of the auriculotemporal nerves seems to be a potential therapeutic option for patients with CM suffering with pain in the temporal region. Neuromodulation is an attractive option because of the lack of side effects and medication habituation in chronic pain states. Additional research is needed to define basic neuroanatomy and mechanisms of pain relief as well as selection criteria for patients with CM.

## REFERENCES

- Schner AJ, Stewart WF, Liberman J, Lipton RB. Prevalence of frequent headache in a population sample. *Headache*. 1998;38:497-506.
- Solomon S, Grosberg BM. Retinal migraine. *Headache*. 2003;43:510.
- Spierings ELH, Schroevers M, Honkoop PC, Sorbi M. Development of chronic daily headache: A clinical study. *Headache*. 1998;38:529-533.
- Silberstein S, Lipton R. Chronic daily headache including transformed migraine, chronic tension type headache, and medication overuse. In: Silberstein S, Lipton R, Dalessio D, eds. *Wolff's Headache and Other Head Pain*, 7th edn. New York, NY: Oxford University Press; 2001:247-282.
- Dodick DW, Aurora SK, Turkel CC, et al. Botulinum neurotoxin type a for treatment of chronic migraine: Double-blind, randomized, placebo controlled PREEMPT trials. 14th International Headache Congress: Abstract LBOR 01. September 12, 2009.
- Silberstein S, Lipton R, Dodick DW, et al. Efficacy and safety of topiramate for the treatment of chronic migraine: A randomized, double-blind, placebo-controlled trial. *Headache*. 2007;47:170-180.
- Spierings ELH. Chronic daily headache. In: Warfield CA, Bajwa ZH, eds. *Principles and Practice of Pain Medicine*, 2nd edn. New York, NY: McGraw-Hill; 2004:221-229.
- Silberstein S, Silberstein J. Chronic daily headache: Long term prognosis following patient treatment with repetitive DHE. *Headache*. 1992;32:439-445.
- Saper JR, Hammel RL, Lake AE, et al. Long-term scheduled opioid treatment for refractory headache: Second interim outcome report. *Headache*. 1998;38:401.
- Jakubowski M, Goor-Aryeh I, Collins B, et al. Terminating migraine with allodynia and ongoing central sensitization using parenteral administration of COX1/COX2 inhibitors. *Headache*. 2005;45:850-861.
- Weiner R, Reed K. Peripheral neurostimulation for control of intractable occipital neuralgia. *Neuromodulation*. 1999;2:217-221.
- Jasper J, Hayek S. Implanted occipital nerve stimulators. *Pain Physician*. 2008;11:187-200.
- Trentman TL, Zimmerman RS, Seth N, Hentz JG, Dodick DW. Stimulation ranges, usage ranges and paresthesia mapping during occipital nerve stimulation. *Neuromodulation*. 2008;11:56-61.

14. Goadsby PJ, Lipton RB, Ferrari MK. Migraine – current understanding and treatment. *N Engl J Med.* 2002;346:257-270.
15. Popeney CA, Alo KM. Peripheral neurostimulation for the treatment of chronic disabling transformed migraine. *Headache.* 2003;43:369-375.
16. Oh MY, Ortega J, Bellote JB, Whitling DM, Alo K. Peripheral nerve stimulation for the treatment of occipital neuralgia and transformed migraine using C1-2-3 subcutaneous paddle style electrode: A technical report. *Neuromodulation.* 2004;7:103-112.
17. Matharu M, Bartsch T, Ward N, et al. Central neuromodulation in chronic migraine patients with suboccipital stimulators: A PET study. *Brain.* 2004;127:220-230.
18. Kosaras B, Jakubowski M, Kainz V, Burstein R. Sensory innervation of the calvarial bones of the mouse. *J Comp Neurol.* 2009;515:331-348.
19. Hammer M, Doleys DM. Perineuronal stimulation in the treatment of occipital neuralgia: A case study. *Neuromodulation.* 2001;4:47-51.
20. Kouroukli I, Neofytos D, Panaretou V, et al. Peripheral subcutaneous stimulation for the treatment of intractable postherpetic neuralgia: Two case reports and literature review. *Pain Pract.* 2009;9:225-229.
21. Rauchwerger JJ, Giordano J, Rozen D, et al. On the therapeutic viability of peripheral nerve stimulation for ilioinguinal neuralgia: Putative mechanisms and possible utility. *Pain Pract.* 2008;8:138-143.
22. Chung JM, Lee KH, Hoi Y, et al. Factors influencing peripheral stimulation produced inhibition of primate spinothalamic tract cells. *Pain.* 1984;19:277-293.
23. Garrison DW, Foreman RD. Effects of transcutaneous electrical nerve stimulation (TENS) on spontaneous and noxiously evoked dorsal horn cell activity in cats with transected spinal cords. *Neurosci Lett.* 1996;216:125-128.
24. Beckmann YY, Secil Y, Kendir AI, Basoglu M. Chronic migraine: A prospective descriptive clinical study in a headache center population. *Pain Pract.* 2009;9:380-384.
25. Jakubowski M, McAllister PJ, Bajwa ZH, Ward TN, Smith P, Burstein R. Exploding vs. imploding headache in migraine prophylaxis with botulinum toxin-A. *Pain.* 2006;125:286-295.